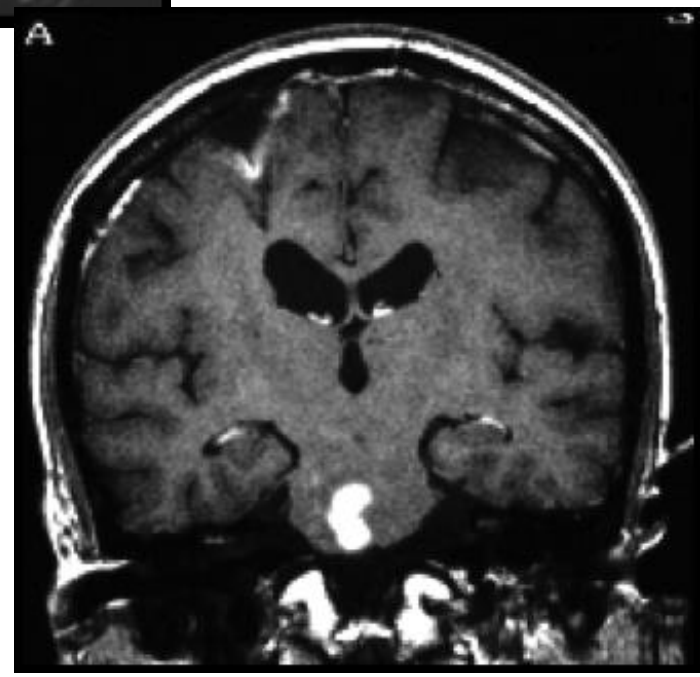
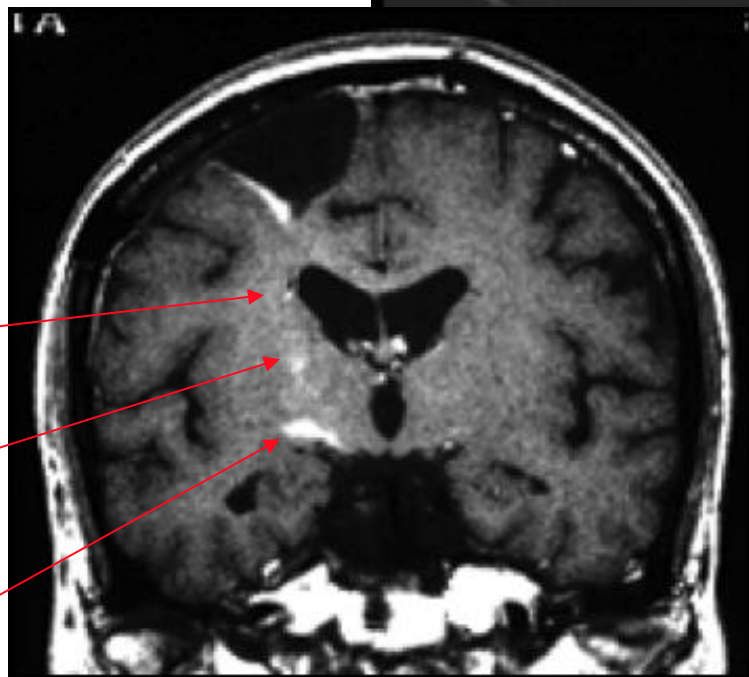
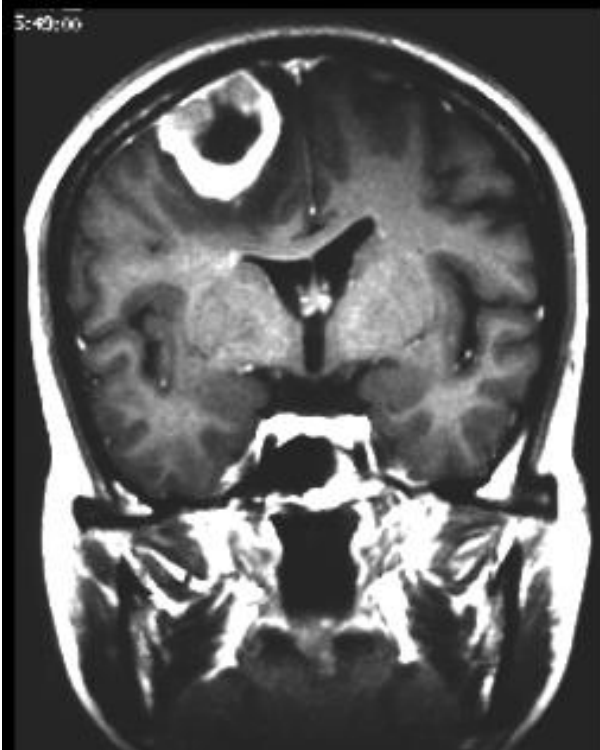


Glioblastomaの浸潤・伸展



矢印のごとく神経
路に沿った細胞の
伸展が認められる

悪性脳腫瘍(グリオーマ)に対する中川らによる 新規開発治療

抗癌剤による化学療法

1. VP-16 + CDDPによる超選択的動注化学療法

Super selective Intraarterial chemotherapy by using microcatheter

2. FdUrdによる腫瘍腔内化学療法

Radiation Therapy

1. I-MRTによる放射線療法

その他

1. Sodium Butyrateによる持続腫瘍腔内あるいは髄腔内投与療法

2. IL-2の動注療法

癌生髄膜炎に対する中川らによる新しい治療の試み

1. Low-dose MTX—1 mg x 2 / day

J Neurooncol 13: 81-89, 1992

2. Ventriculo-Lumbar Perfusion Chemotherapy with MTX & Ara-C

Surg Neurol 45: 256-64, 1996

3. Continuous Intrathecal Infusion of MTX

4. Treatment of meningeal carcinomatosis resistant to MTX (MTX + 6TG, Verapamil)

90th AACR, 1999, Philadelphia

5. Repeated bolus administration of 5 Fluoro-2' -deoxyuridine (FdUrd)

J Neurooncol 37: 115-121, 1998; J Neurooncol 45: 175-183, 1999

Cancer Chemother Pharmac 43:247-256, 1998

6. Continuous intrathecal administration of FdUrd

Neurosurgery 57:266-280, 2005

7. Continuous intrathecal administration of Sodium Butyrate (NaB)

95th AACR, 2004, Orlando; 96th AACR, 2005, Anaheim, ICACT, 2006, Paris; ECCO 15/ESMO 34, 2009, Berlin; 43rd ASCO, 2007, Chicago

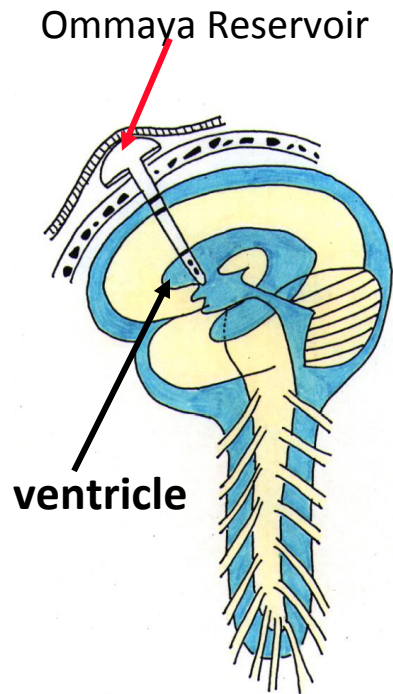
8. NS-101 (DepoCyt: Cytarabine徐放剤)による髄膜癌腫症の治療-Phase I-

癌と化学療法 34: 1799-1805, 2007

9. Basic research for intrathecal administration of Y-27632 (Rock inhibitor)

Mol Cancer Res 3:425-433, 2005

Survival in 34 patients with meningeal carcinomatosis (1984~1990)



Treatment	Number of cases	MST (days) (mean \pm SEM)
No treatment	5	18 \pm 3 (11-30)
IT only	*** 11	177 \pm 41 (20-436)
IT + SC	** 8	128 \pm 32 (34-485)
IT + RT	* 4	249 \pm 72 (150-461)
IT + SC + RT	* 6	118 \pm 33 (20-215)

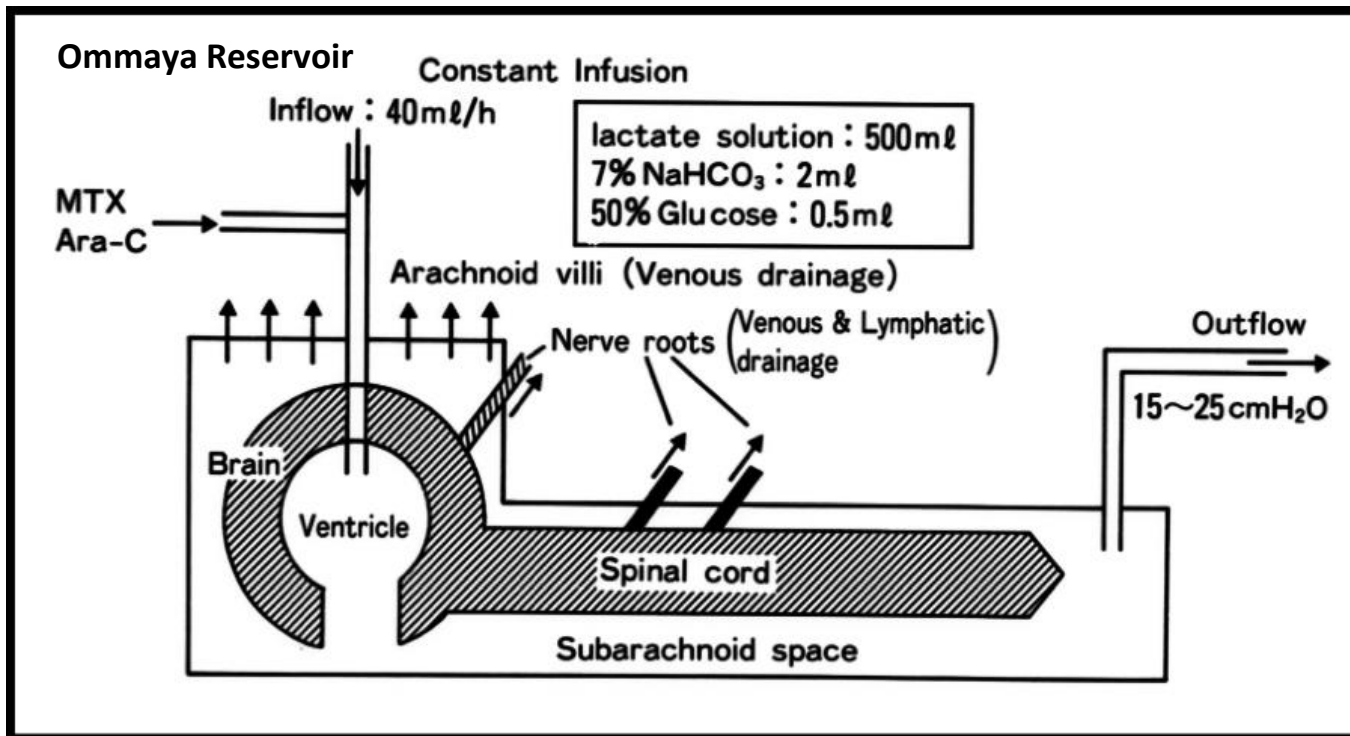
IT: intrathecal chemotherapy with MTX and/or Ara-C

SC: systemic chemotherapy, RT: radiation therapy

*, $P < 0.05$; **, $p < 0.001$; ***, $p < 0.005$

Ventriculolumbar perfusion chemotherapy (VLP) with MTX & Ara-C

Nakagawa H, et al.:Ventriculolumbar perfusion chemotherapy with methotrexate and cytosine arabinoside for meningeal carcinomatosis: A pilot study in 13 patients. **Surg Neurol 45: 256-64, 1996**



Clinical response to ventriculolumbar perfusion (VLP) chemotherapy

Pt. No.	* cranial nerves	** spinal roots	Ambulatory pre	Status post	CSF examination	Responding CSF parameters	Response grade	Survival time(months)
1.	5/7	3/3	bedridden	walking	normalization	Ce, BG, Cy	good	12.0
2.	5/5	1/1	walking	walking	no response		minor	8.0
3.	1/9	0/2	bedridden	bedridden	no response		none	3.0
4.	1/2	2/2	walking(a)	walking(a)	response	BG, Cy	moderate	7.0
5.	2/2	2/3	walking(a)	walking(a)	response	Ce	minor	7.0
6.	1/2	1/2	bedridden	bedridden	normalization	Ce, BG, Cy	moderate	4.0
7.	6/6	2/2	bedridden	walking	normalization	Ce, BG, Cy, MBP	good	6.0
8.	1/1	3/3	walking(a)	walking	normalization	Ce, BG, Cy, MBP	good	18.0
9.	0/5	0/4	bedridden	bedridden	slight response	Ce	none	4.0
10.	6/13	3/3	walking(a)	walking	normalization	Ce, BG, Cy, MBP	good	9.0
11.	4/6	3/3	bedridden	walking	response	Ce, BG	moderate	6.0
12.	8/10	1/2	walking	walking	normalization	Ce, BG, Cy, MBP	good	1.0
13.	2/2	0/0	walking	walking	response	Ce, BG, MBP	good	8.0

* No. of improved cranial nerves

** No. of improved spinal root signs (motor, sensory, tendon reflex, urinary incontinence : total, 4 / no. of involved spinal roots.

Ce, cell count; BG, beta-glucuronidase; Cy, cytology; MBP, myelin basic protein

Clinical response to ventriculolumbar perfusion (VLP) chemotherapy

1. Ambulatory status

walking with assist ~bedridden  walking : 5 / 7

2. Improved cranial nerves : 12 / 13

3. Improved spinal roots signs : 10 / 13

4. CSF examination

normalization : 6

response : 5

no response : 2

5. Survival time : 1 ~ 18 months , 7.2 ± 1.2 months (M \pm SEM) (n=13)

Remission period : 0 ~ 13 months , 4.0 ± 1.0 (M \pm SEM) (n=13)

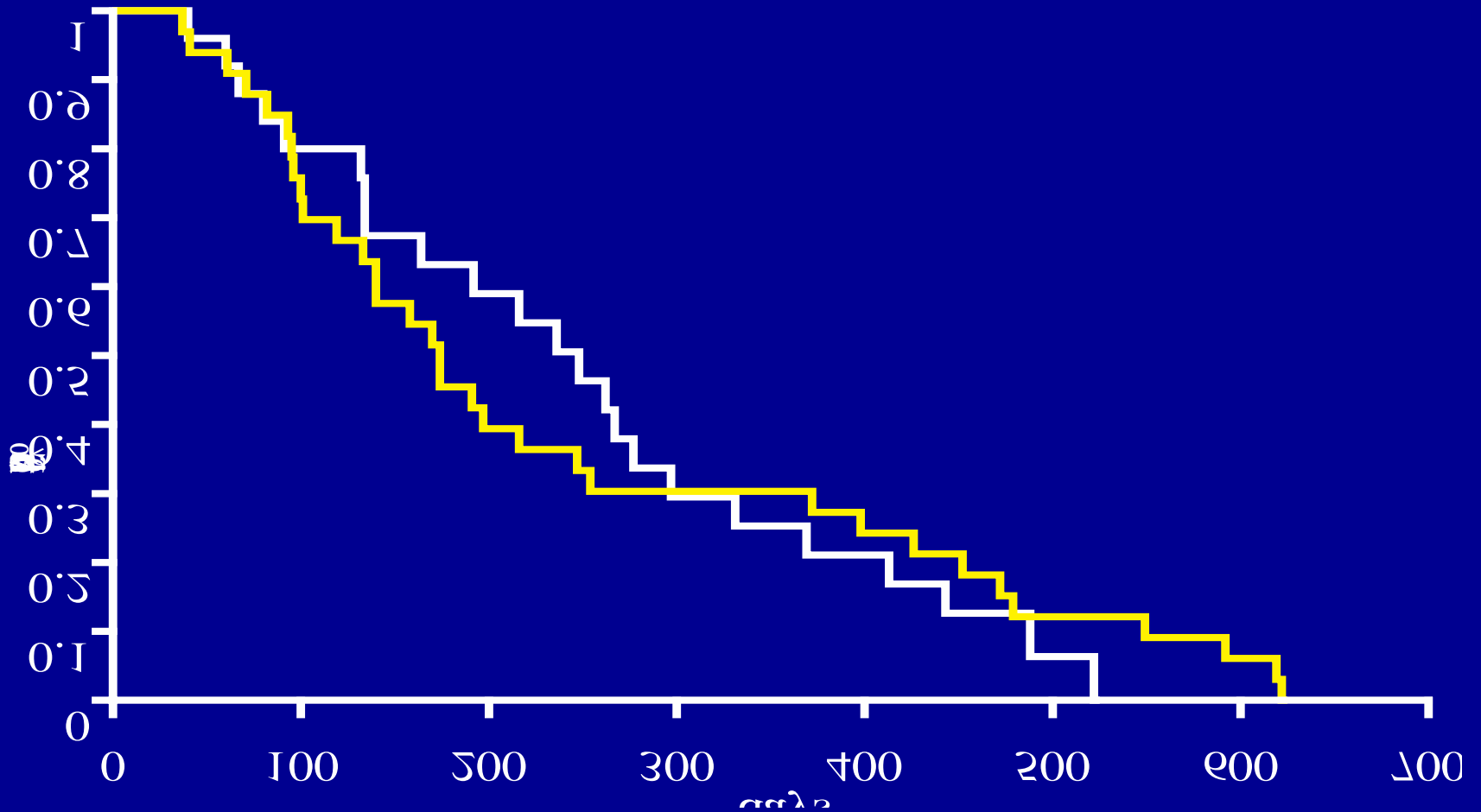
Bolus or Continuous Intrathecal Administration of 5-fluoro- 2-deoxyuridine (FdUrd)

Basic Yamada M, Nakagawa H, et al.: In vitro study on intrathecal use of 5-fluoro-2' - deoxyuridine (FdUrd) for meningeal dissemination of malignant brain tumors. J Neurooncol 37: 115-121, 1998

clinical Nakagawa H, et al. : Clinical trial of intrathecal administration of 5-fluoro- 2' -deoxyuridine for treatment of meningeal dissemination of malignant tumors.
J Neurooncol 45: 175-183, 1999

Nakagawa H, et al. : Continuous intrathecal administration of 5-fluoro-2' -deoxyuridine for the treatment of neoplastic meningitis. Neurosurgery 57:266-280, 2005.

Survival of Patients with Leptomeningeal Carcinomatosis treated by Continuous Intrathecal Chemotherapy with FdUrd-Comparison with the Historical Control (the survival of patients treated with MTX and Ara-C)



Historical control: the patients were treated by bolus intrathecal administration of MTX (5 mg) and Ara-C (20 mg) twice a week

Results

1. No apparent toxicity has been observed to date.
2. Evidence of CSF response was observed in 13 pts.
3. Headache and nausea was improved in all pts and cranial nerve impairment was improved in 12 pts.
4. MR image response was observed in 5 pts.
5. Overall response was observed in 14 pts when cases of stable disease were excluded from the responding cases.
6. Survival time (mean \pm sem days, n) was 251 ± 30 , 25. The survival times in pts with and without WBI were 182 ± 37 , 8 and 285 ± 39 , 17, respectively ($p=0.057$).

Conclusion

Continuous intrathecal administration of FdUrd, when a subcutaneously implantable infusion pump is available, may be useful for the treatment of leptomeningeal carcinomatosis, especially for maintenance therapy in outpatients, although WBI seems to cause adverse effects.

Further studies in larger populations are necessary to properly evaluate the benefits of continuous intrathecal FdUrd chemotherapy.

Clinical Trial of Continuous Intrathecal Administration of Sodium Butyrate in Leptomeningeal Carcinomatosis

Sodium butyrate has been expected to be clinically useful because of its effects on cellular differentiation and apoptosis and its inhibition of invasion with minimal effects on metabolism since sodium butyrate is present at high concentrations in the membrane of the intestine as a metabolite of food.

Basic Research

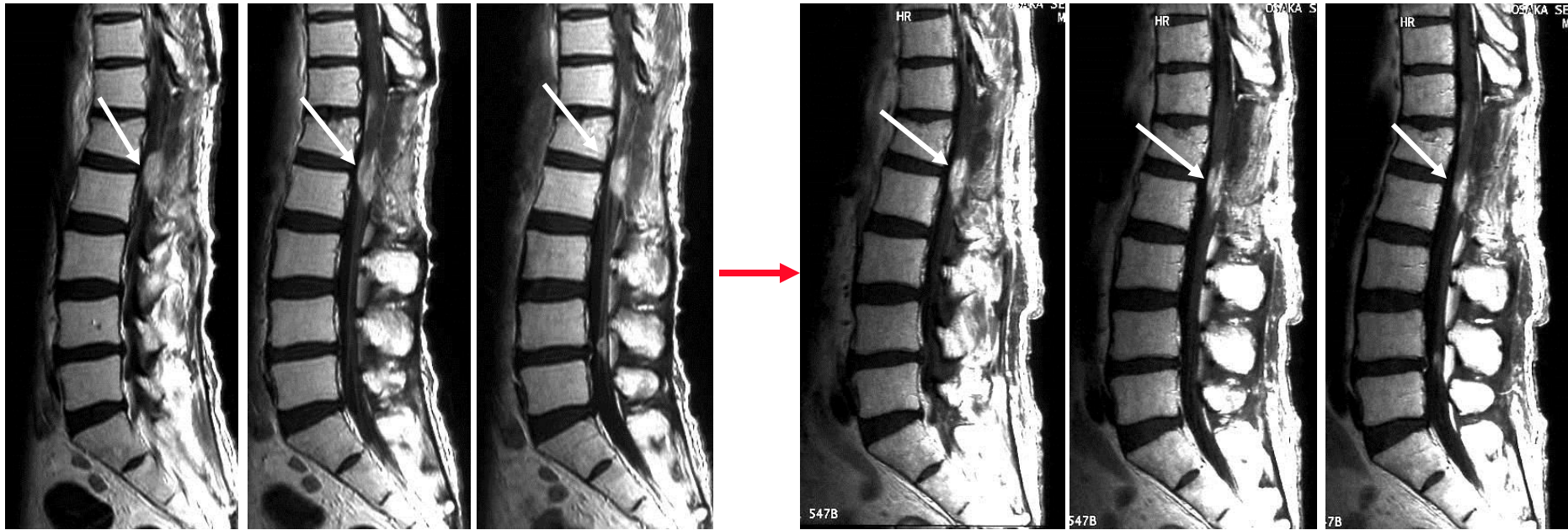
Nakagawa H, et al. : Intrathecal or intracavitary administration of sodium butyrate to treat neoplastic meningitis and malignant glioma.
95th AACR, Orlando, USA, March, 2004

Clinical Trial

Nakagawa H, et al. : Clinical trial of continuous intrathecal or intracavitary infusion of sodium butyrate for leptomeningeal carcinomatosis or recurrent malignant glioma.
96th AACR, Anaheim, CA, USA, April 16-20, 2005

Nakagawa H, et al. : Clinical trial of continuous intrathecal or intracavitary infusion of sodium butyrate for recurrent or progressive malignant glioma.
98th ASCO, Chicago, IL, USA, June 1-5, 2007

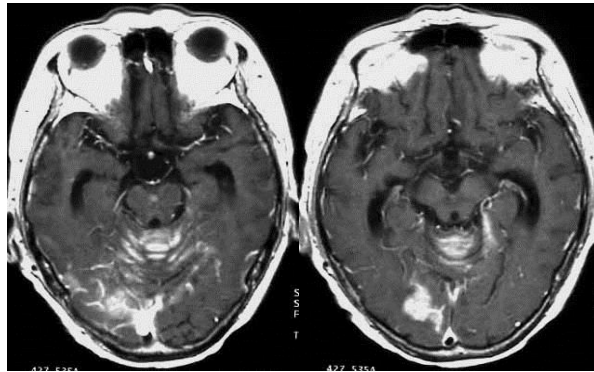
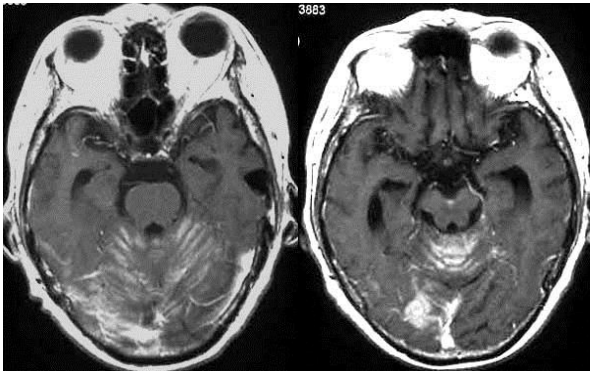
Patient 1 : spinal dissemination derived from esophageal cancer



**Spinal MRI at the commencement of
Continuous IT of NaB**

One month later

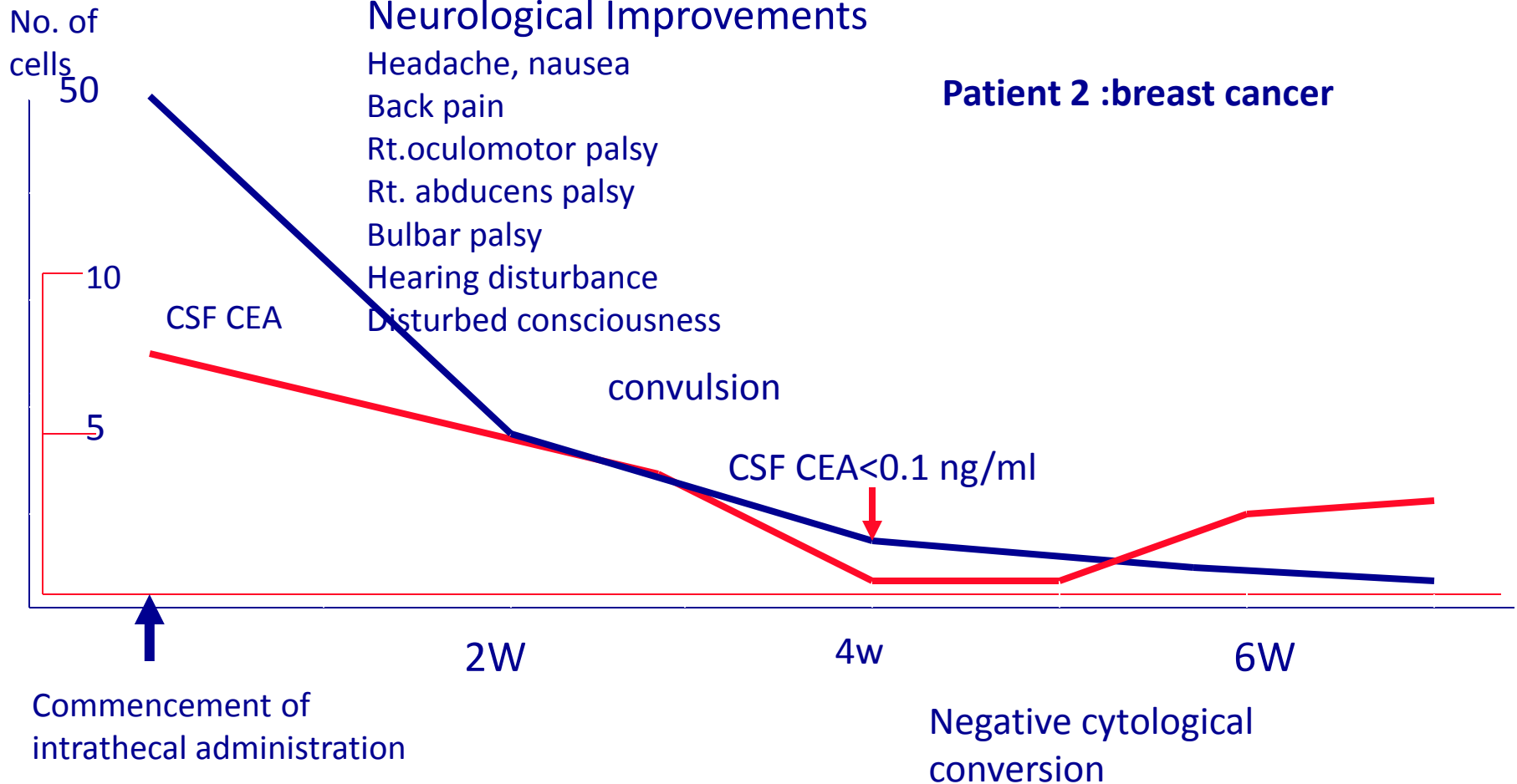
Improved points: pain -free from morphine hydrochloride and pentazocine



Neurological Improvements

- Headache, nausea
- Back pain
- Rt. oculomotor palsy
- Rt. abducens palsy
- Bulbar palsy
- Hearing disturbance
- Disturbed consciousness

Patient 2 :breast cancer



Results of continuous intrathecal infusion of sodium butyrate in patients with leptomeningeal carcinomatosis

Pt. No.	CSF Response	Improved Symptoms & Signs	Response on MRI	Adverse effects & complications	PFS (months)	Survival (months)
1	reponse	pain relief	response	none	2.5	2.5 dead
2	response	cranial nerves meningeal signs increased appetite increased activity	stable	none	2.0	2.0 dead
3	no response	headache cauda equina syndrome cranial nerve (rt.NV)	stable	convulsion	0	11.0 dead
4	response	diplopia, taste	stable	loss of appetite	4.0	4.0 dead
5	response	headache	stable	bacterial meningitis	3.0 <	4.0 dead
6 ^g	response	level of consciousness	stable	convulsion	5.0 <	38.0 dead
7 ^g	response	level of consciousness ataxic respiration	response	bradycardia convulsion	18.0	28.0 alive
8 ^g	response	none	no response	bacterial meningitis	0	5.0 dead
9 ^g	response	none	response	none	7.0	15.0 dead

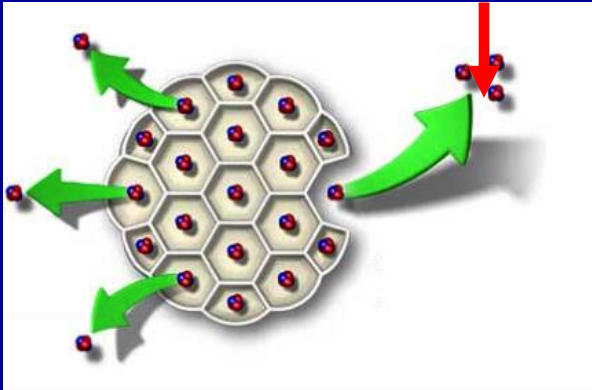
g, malignant glioma, PFS, progression free survival

NS-101(DepoCyt)による髄膜癌腫症(癌性髄膜炎)の 治療-Phase I study-

cytarabine liposome injection

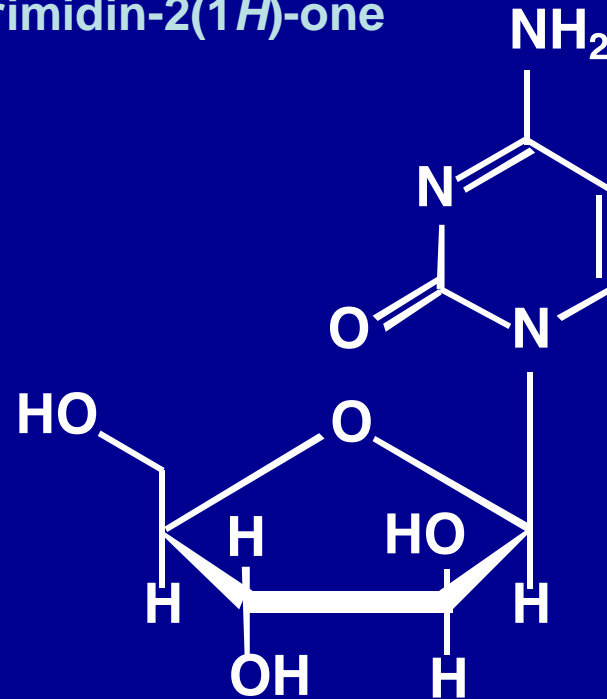
化学名：

4-Amino-1-β-D-arabinofuranosylpyrimidin-2(1H)-one



分子式： $C_9H_{13}N_3O_5$

分子量：243.22

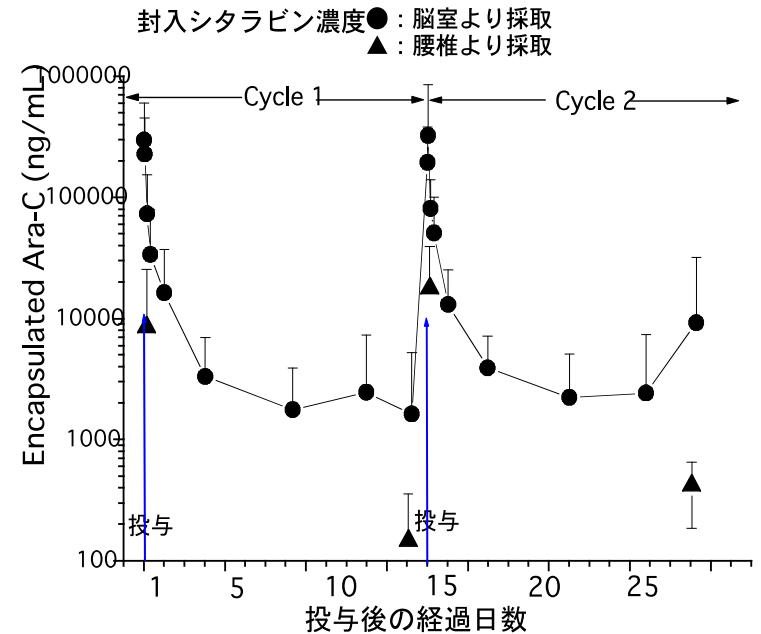
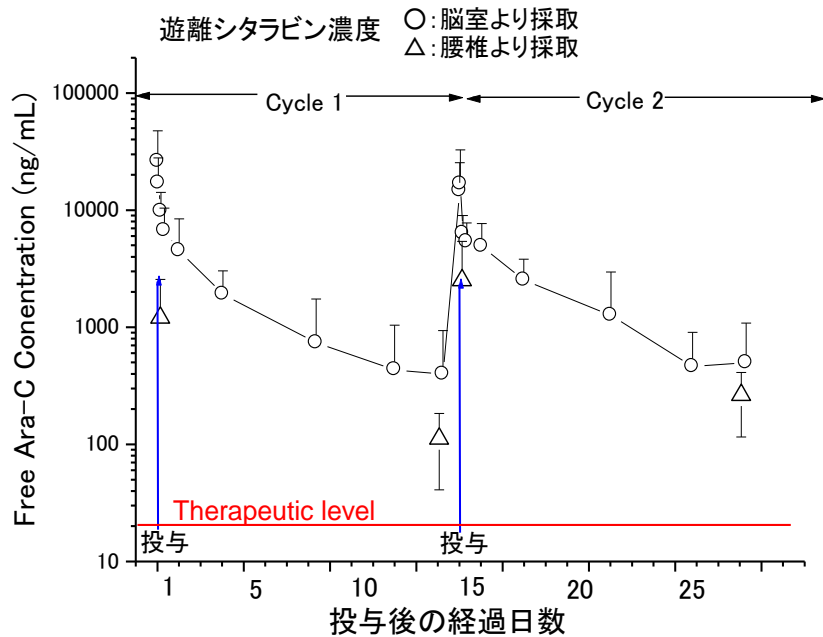


2週間に1回投与で有効濃度を維持することが可能

外国における承認状況

国	承認、適応
米国 (FDA)	1999.4.1 承認 (Accelerated Approval) リンパ腫由来の髄膜癌腫症 intrathecal treatment of lymphomatous meningitis
カナダ (TPP)	1999.11.17 承認 固形腫瘍及びリンパ腫由来の髄膜癌腫症 intrathecal management of neoplastic meningitis due to solid tumours or lymphoma
EU (EMA)	2001.7.11 承認 (中央審査方式) リンパ腫由来の髄膜癌腫症 intrathecal treatment of lymphomatous meningitis. In the majority of patients such treatment will be part of symptomatic palliation of the disease

Time course of Ara-C Concentration in CSF

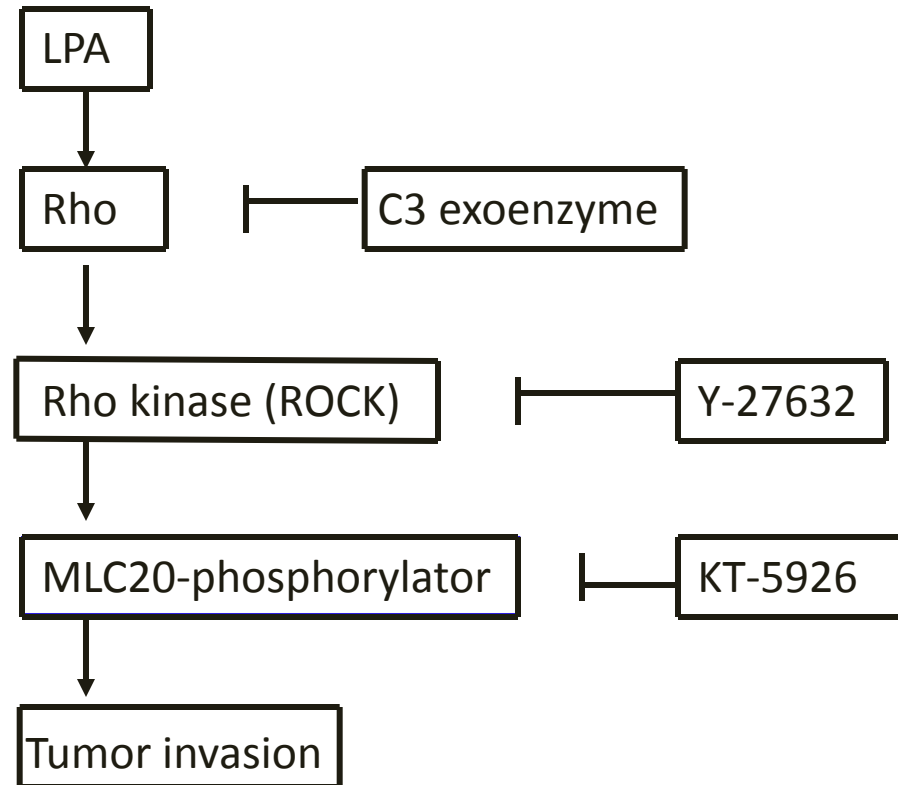
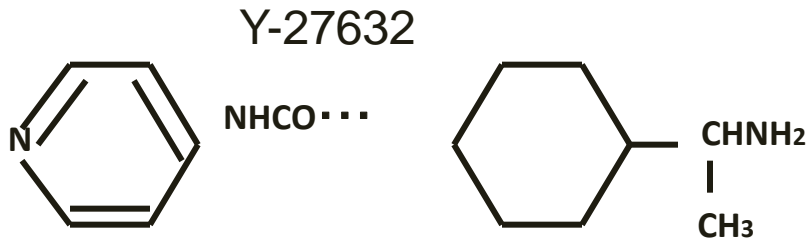


Results of Phase I Study of NS-101

- 1. CSF Concentrations of Free Ara-C and Encapsulated Ara-C at 2 wks : > 20 ng/ml**
- 2. CSF: CR, 2; PR, 6; NC, 0; PD, 0; NE, 1**
- 3. Clinical Effects: Response, 5(4) ; No response, 2 ; NE, 2**
- 4. MRI: Improved, 1 ; No Change, 6 ; Progressive, 1**
- 5. Adeverse Effects:**
 - Grade-1, 4**
 - Grade-2, 6**
 - Grade-3, 3**
 - Grade-4, 0**

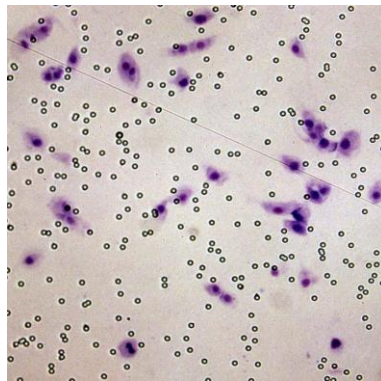
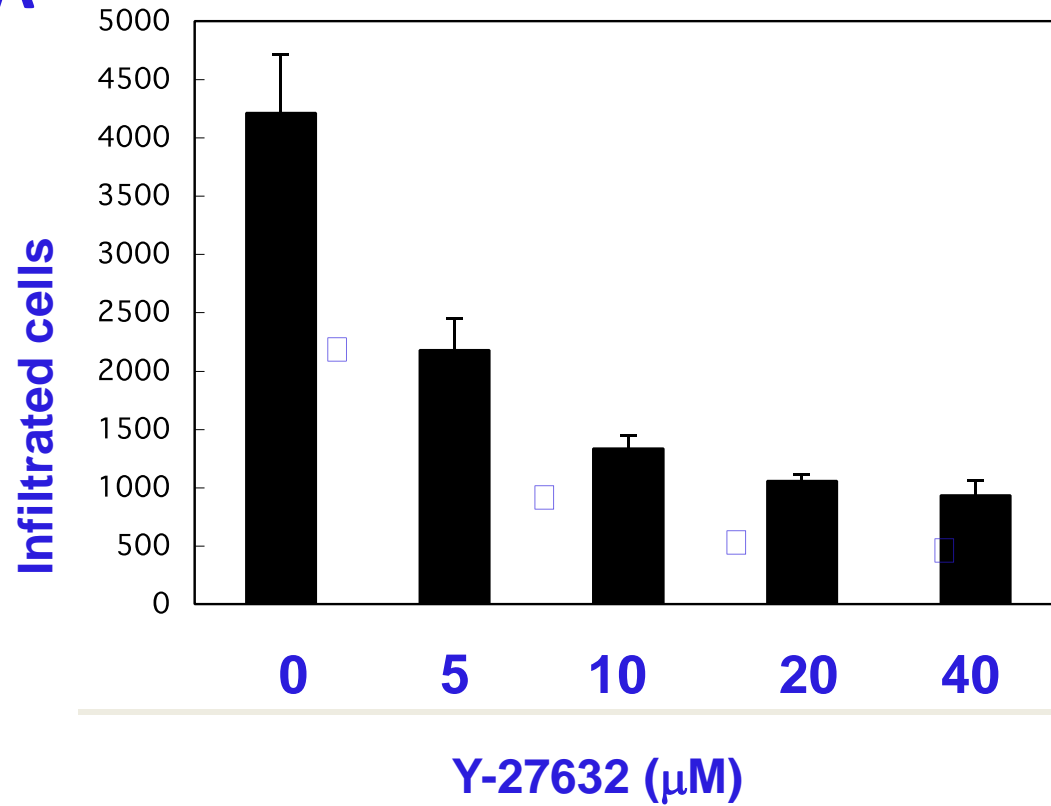
Intrathecal administration of Y-27632 (Rock inhibitor)

Rho-Family Protein and Y-27632

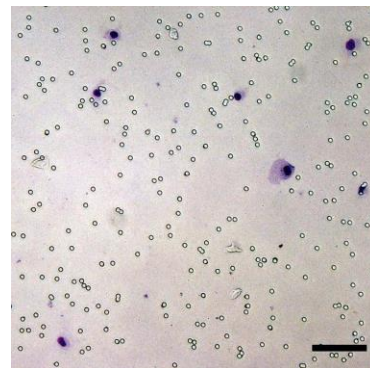


Nakagawa H, et al. : Intrathecal administration of Y-2732, a specific Rho-associated kinase inhibitor, for rat neoplastic meningitis. *Mol Cancer Res* 3: 425-433, 2005.

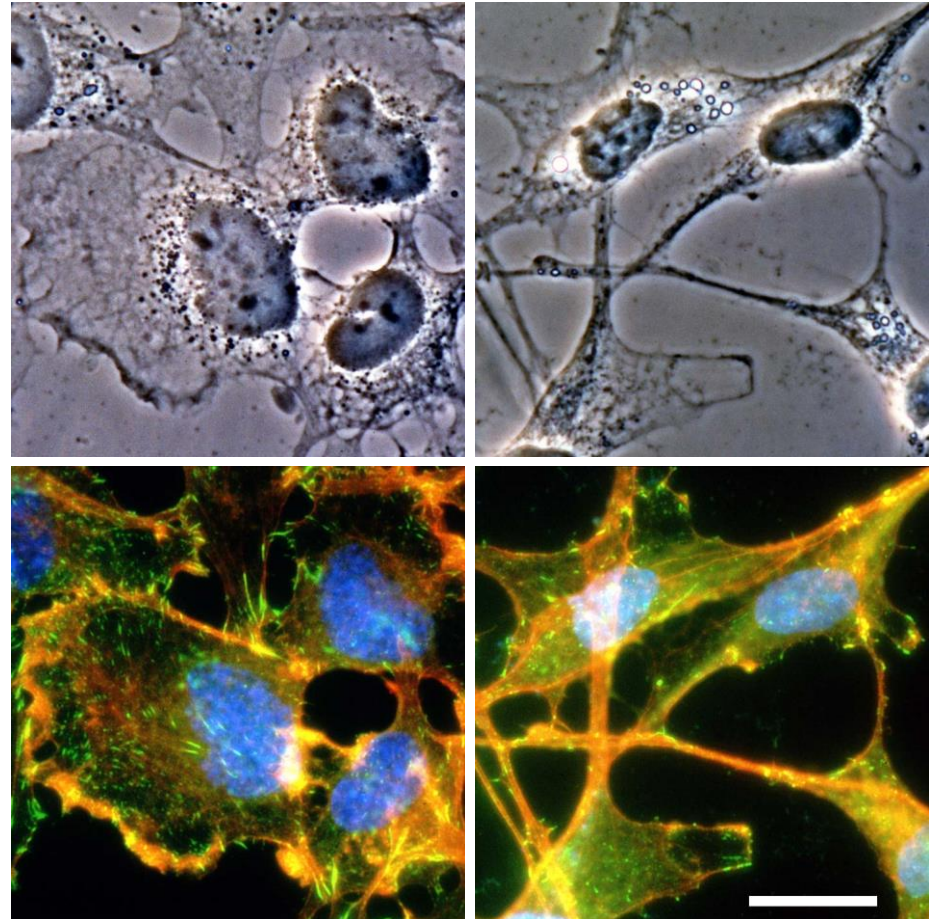
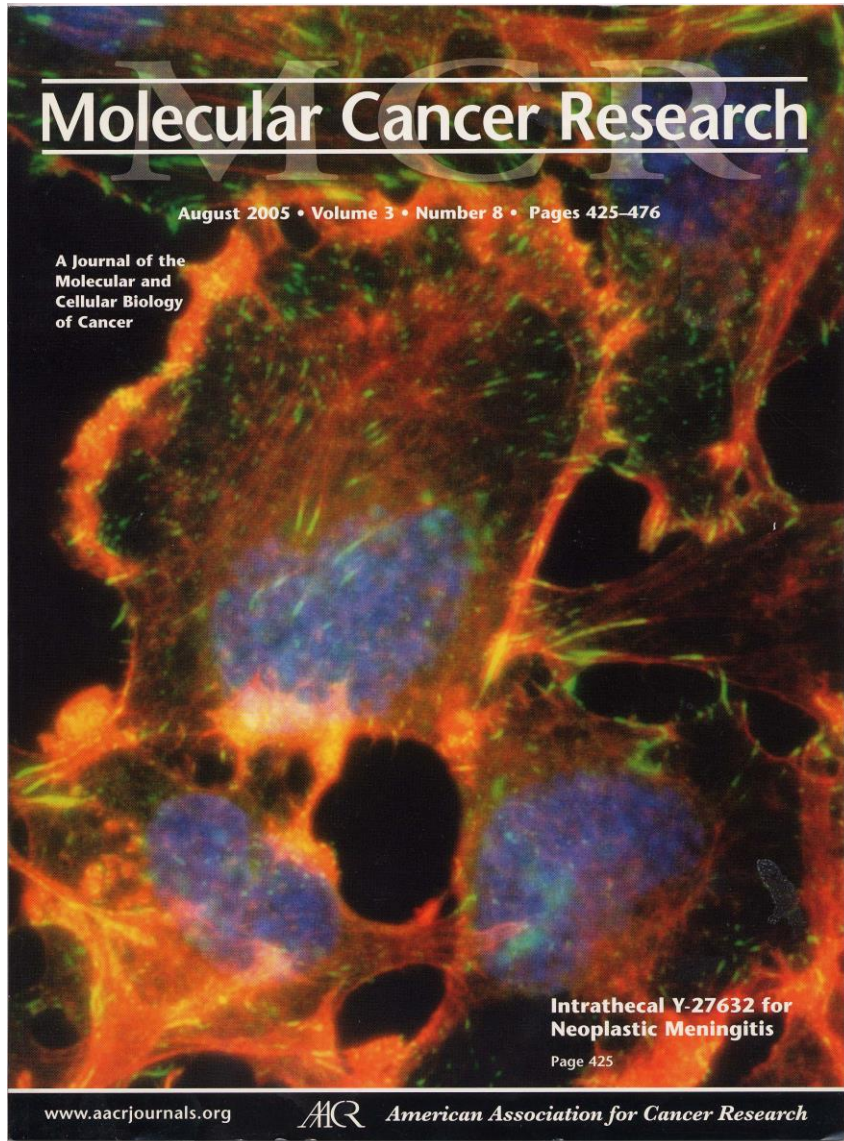
A



Control



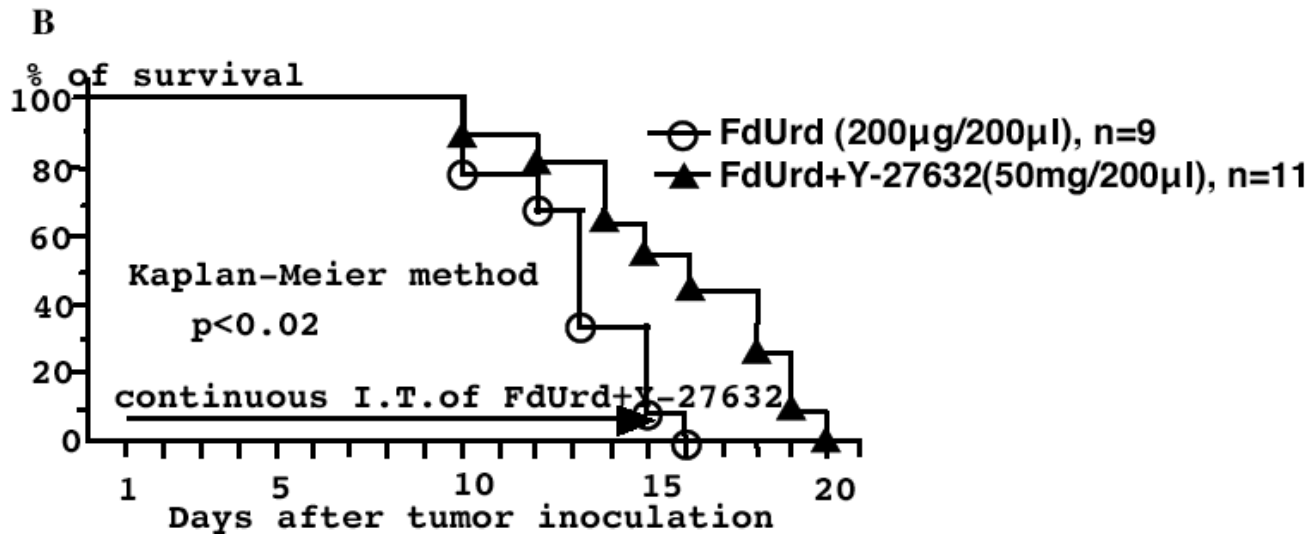
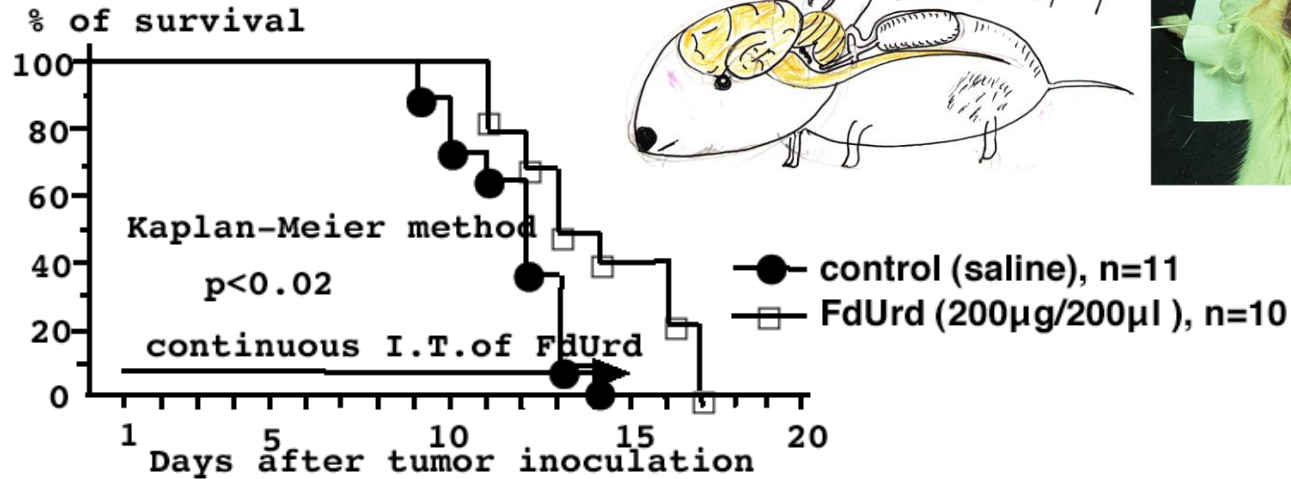
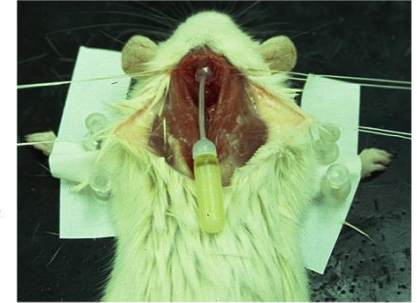
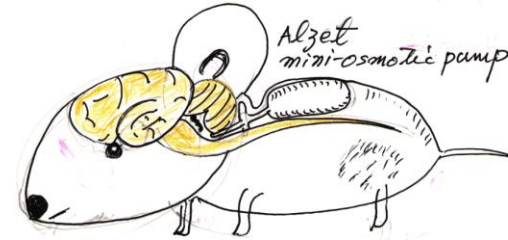
10 μM Y-27632



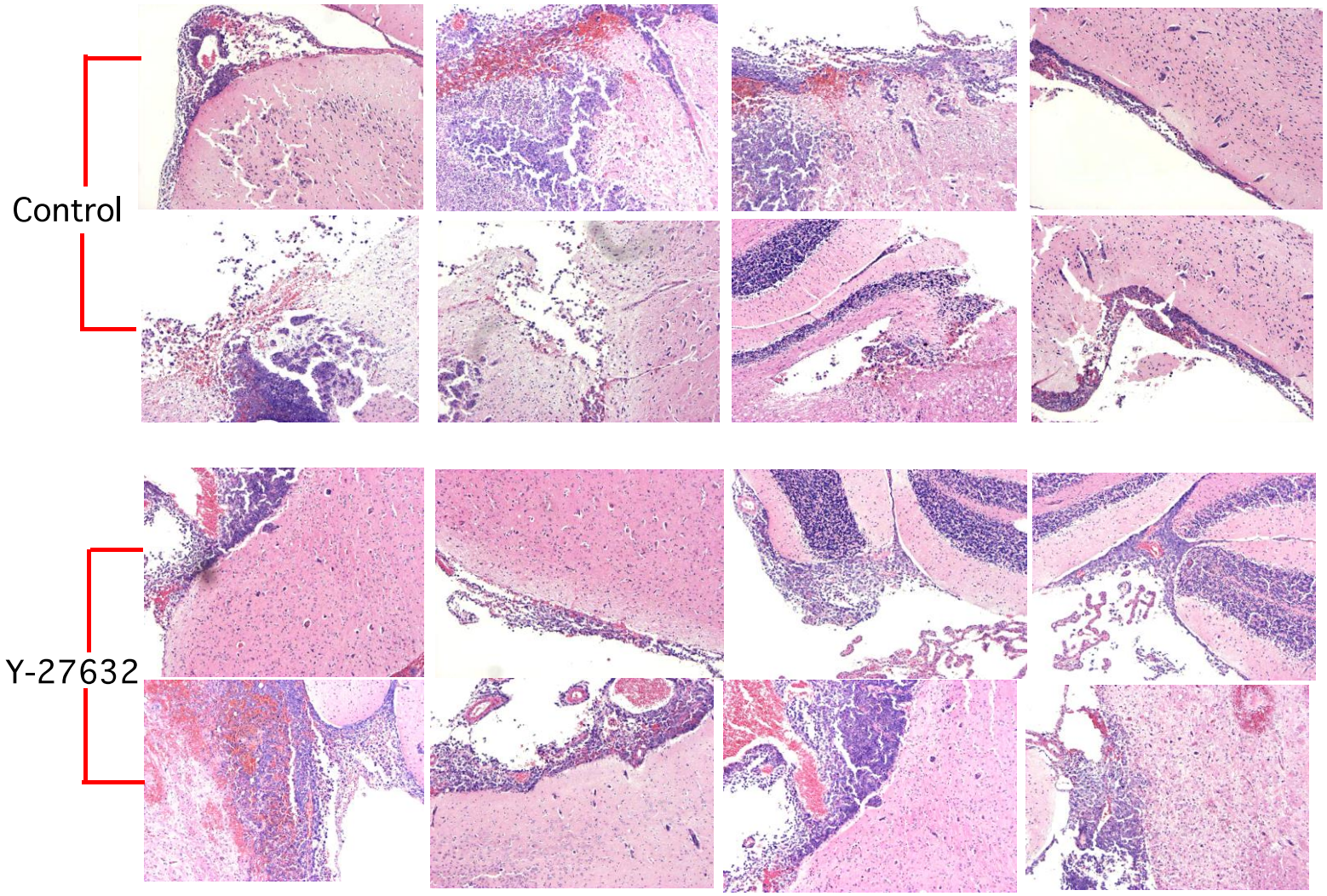
投稿論文の表紙になった

Anti-tumor effects of continuous intrathecal injections of Y-27632 on rat leptomeningeal carcinomatosis using Walker 256 carcinoma cells

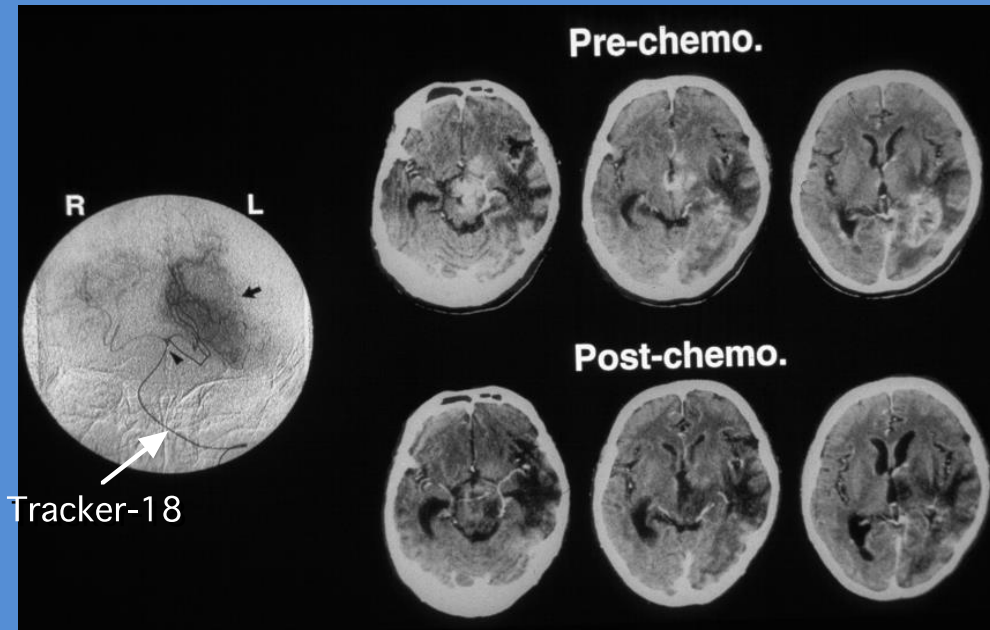
ラット髄腔内への薬剤持続投与モデル 模式図



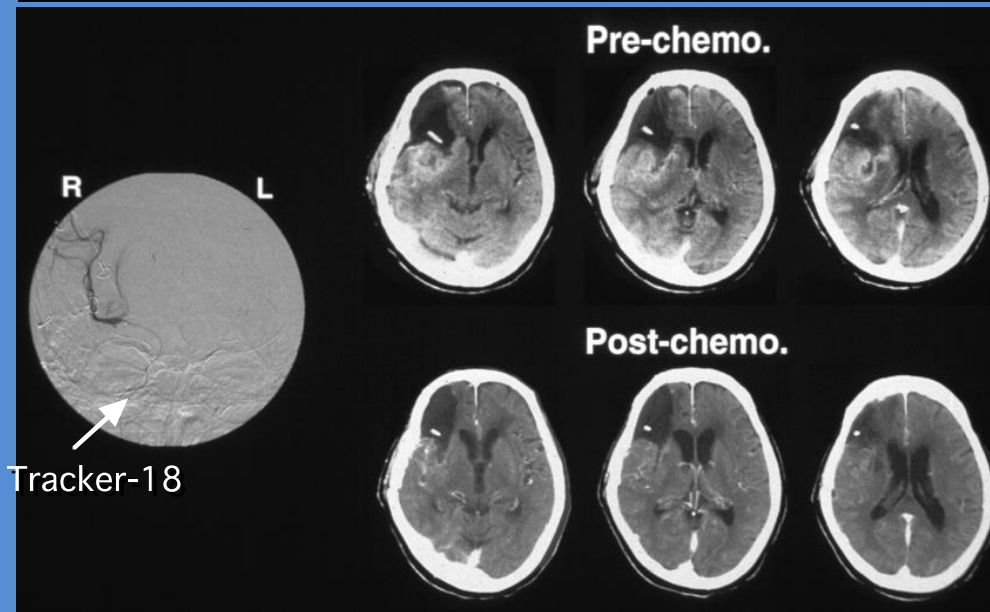
Histological appearances at 14 days after tumor inoculation




再発例



初発例



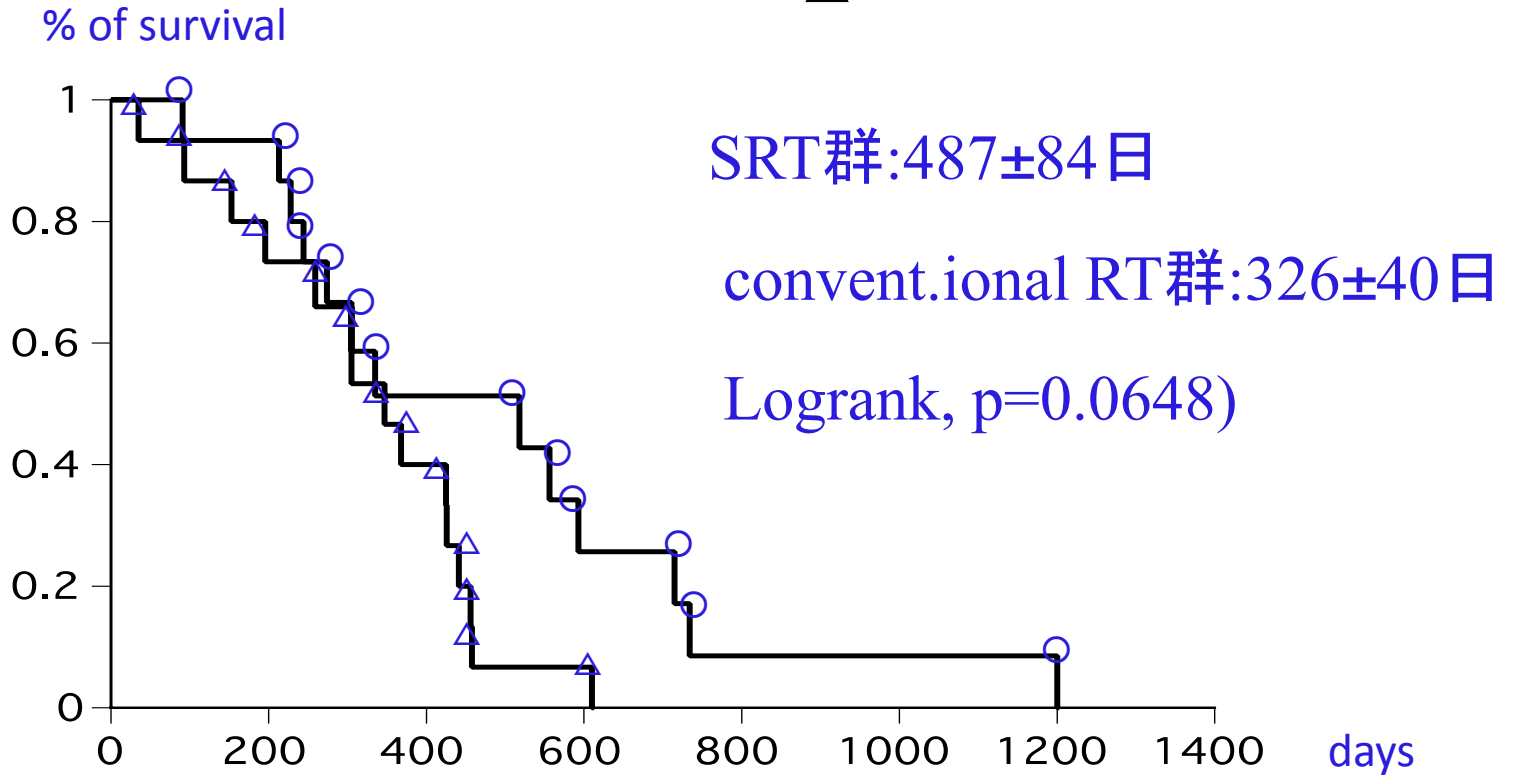
Nakagawa H, ET AL: Selective intra-arterial chemotherapy with a combination of etoposide and cisplatin for malignant gliomas. Surg Neurol 41 : 19-27, 1994



m3-Micro-Multileaf Collimator (Brain LAB社製)

○—○ SRT with mMLC

△—△ Conventional RT



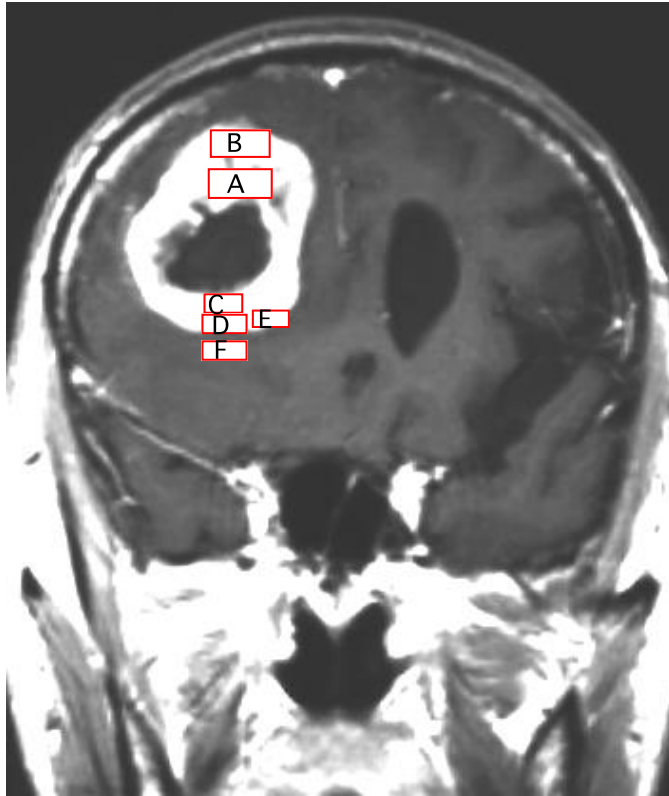
中川秀光:先端医療シリーズ18・脳神経外科,脳腫瘍の最新医療、高倉公朋監修、第6章放射線治療、4.マイクロマルチリーフ照射、pp.203-209, 2003、先端医療技術研究所発行。

中川秀光、西山謹司:マイクロマルチリーフ療法、Clinical Neuroscience 21:566-567, 2003.

5-fluoro-2'-deoxy uridine (FdUrd)の基礎から臨床

Intrathecal administration of FdUrdで米国特許取得

Concentrations of FdUrd in tumor and surrounding brain after intracavitary injection of FdUrd



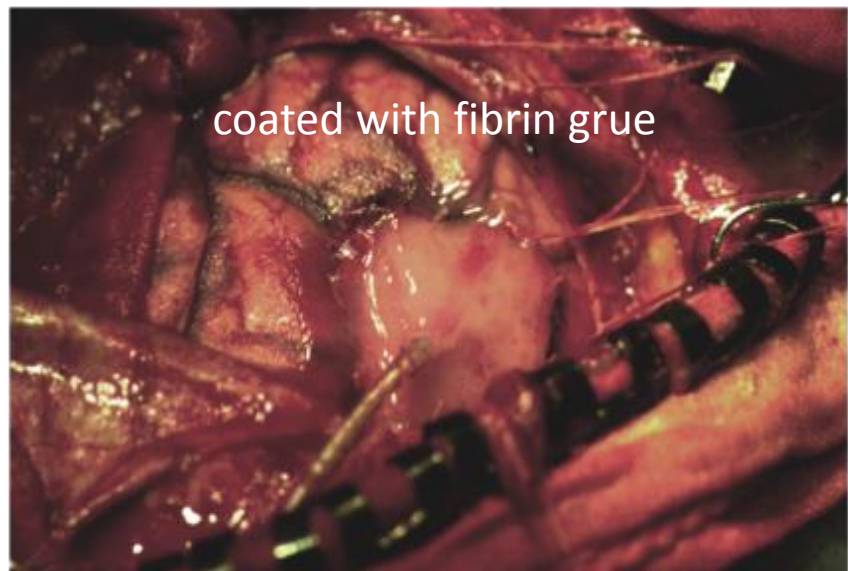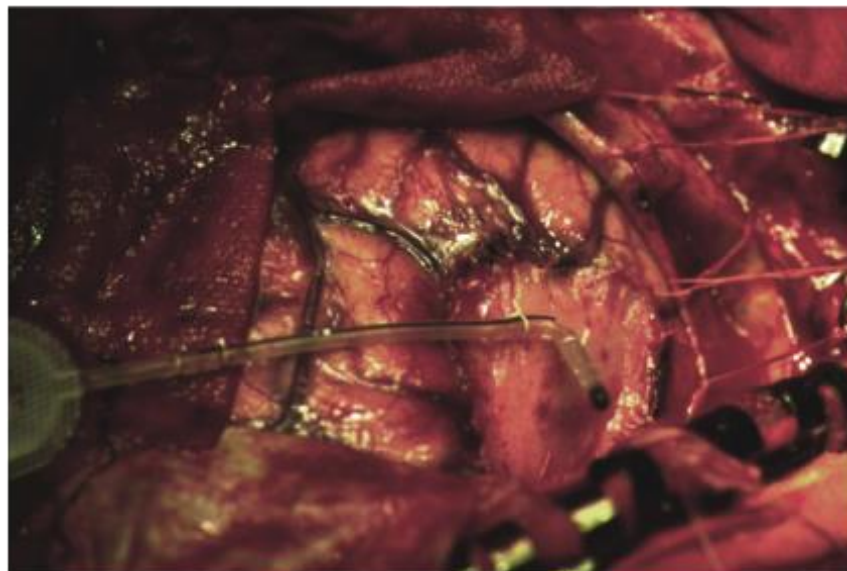
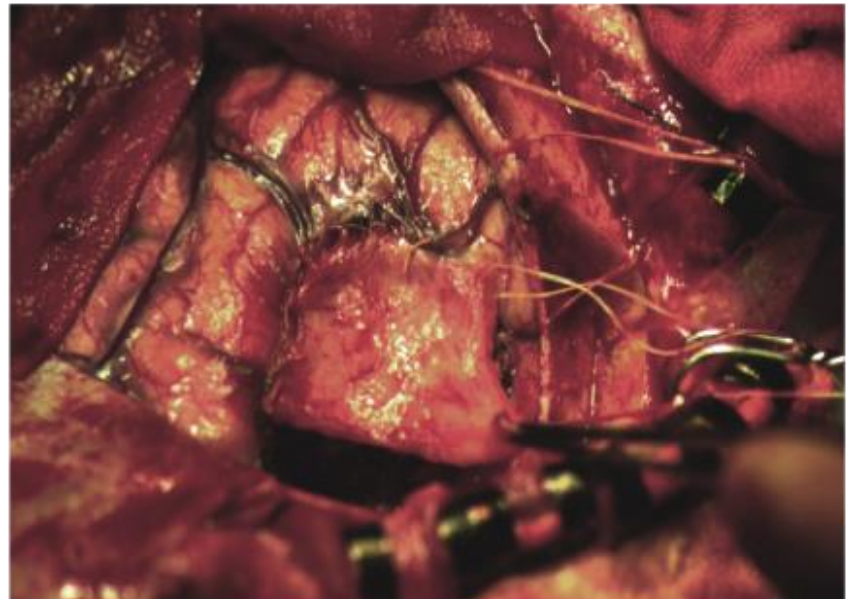
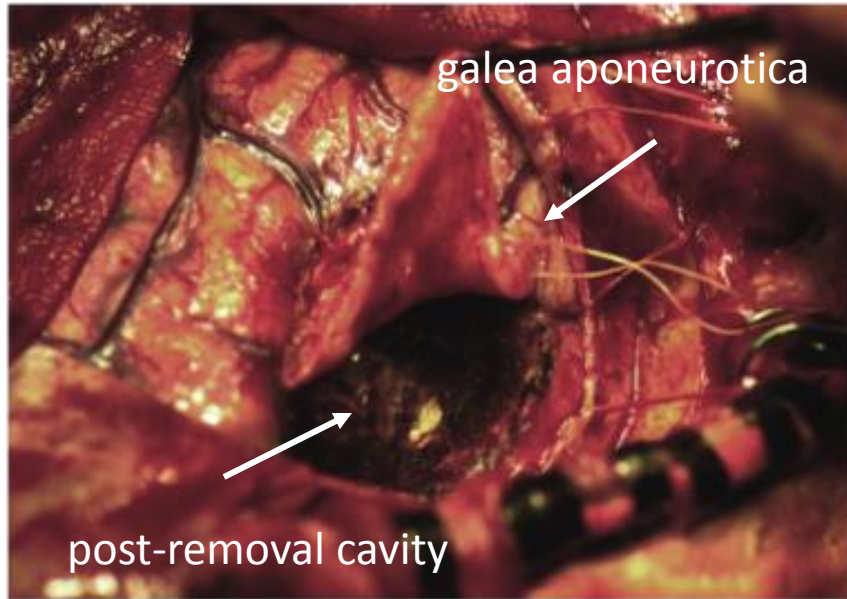
Time after injection	FdUrd
A	31.8 ng/g
B	7.7
C	73.6
D	9.9
E	3.4
F	0.8

Ten microgram of FdUrd was injected and the breadth of tissues sampled were 5.0 mm.
FdUrd was not detected in the plasma during the course of therapy

Nakagawa H, et al.: Clinical trial of intrathecal administration of 5-fluoro-2'-deoxyuridine for treatment of meningeal dissemination of malignant tumors. *J Neurooncol* 45: 175-183, 1999

Nakagawa H, et al: Intracavitary chemotherapy with 5-fluoro-2'-deoxyuridine (FdUrd) in malignant brain tumors. *Jpn J Clin Oncol* 31: 251-258, 2001

Remodeling of postoperative cavity to closed cavity for intracavitary chemotherapy with FdUrd



Study Population

Pt.No.	Age/Sex	Diagnosis	Dose(μ g) X Times	Other therapy	Result
1 S.U.	68/F	glioblastoma	1 x 25	none	PR
2 S.H.	59/F	metastatic brain tumor (lung)	2 x 25	none	stable
3 T.O.	61/M	metastatic brain tumor (lung)	1 x 10	chemo + Ra	N.E.
4 O.T.	50/M	recurrent anaplastic astrocytoma	1 x 25	none	CR
5 K.E.	57/F	metastatic brain tumor (breast)	5 x 21	none	CR
6 S.H.	42/F	metastatic brain tumor (ovary)	5 x 13	none	PD
7 M.U.	53/F	glioblastoma	10 x 30	none	PD
8 K.K.	24/F	glioblastoma	5 x 50	none	stable
9 K.K.	58/F	recurrent glioblastoma	5 x 25	none	PD
10 K.F.	60/F	glioblastoma	5 x 29	Ra	CR
11 T.H.	63/M	metastatic brain tumor (lung)	5 x 25	none	CR
12 H.T.	59/M	malignant change (glioblastoma)	5 x 38	Ra	CR

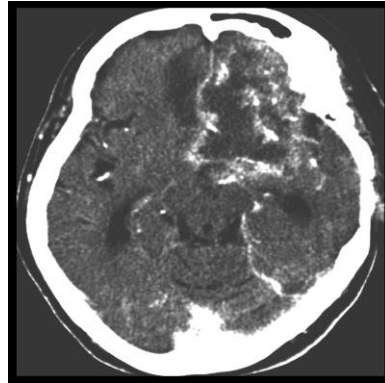
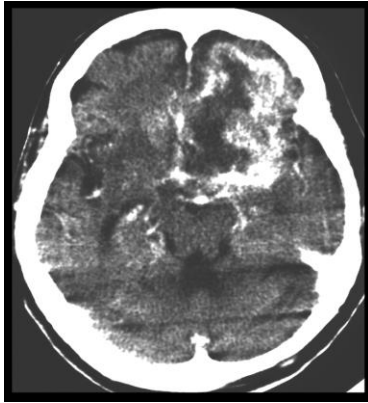
pre-chemotherapy

post-chemotherapy

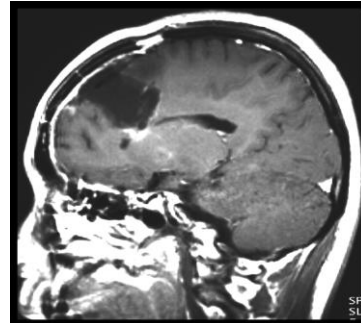
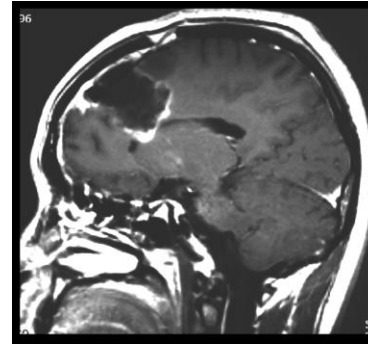
pre-chemotherapy

post-chemotherapy

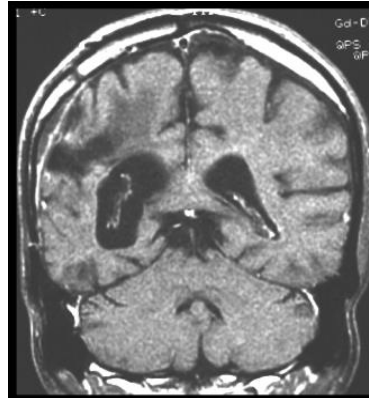
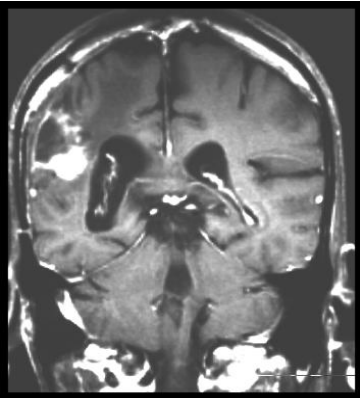
1. S.U.



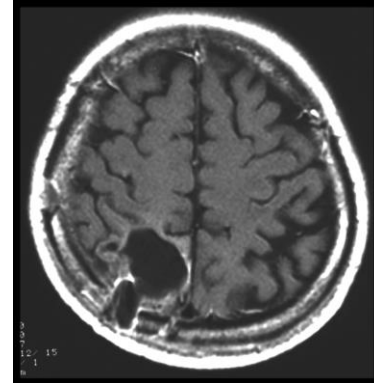
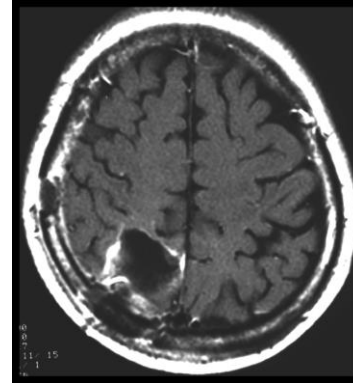
8.K.K.



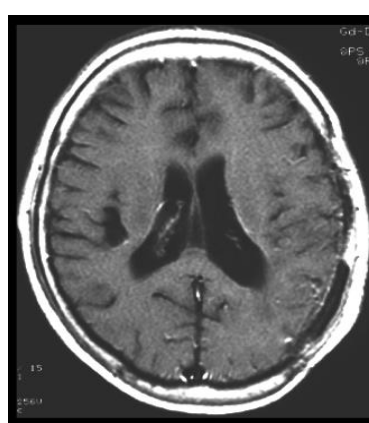
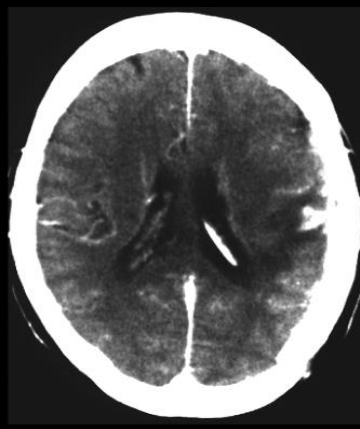
4.O.T.



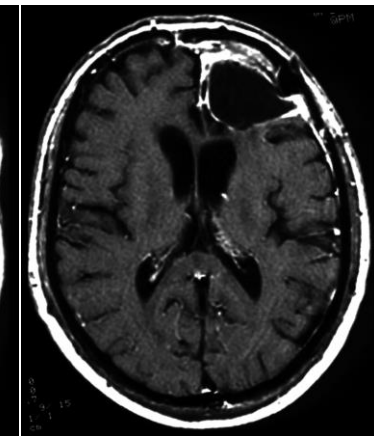
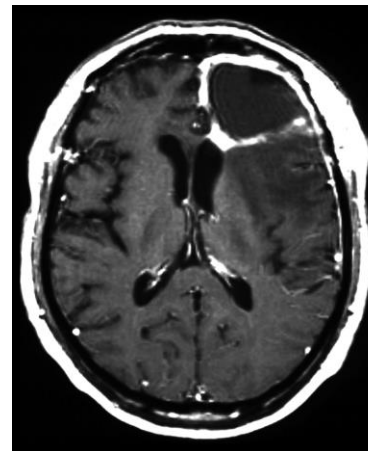
10. H.F.



5.K.E.



12.HT



Nakagawa H, et al.: Experimental study on the effect of intracarotid recombinant IL-2 on brain capillary permeability of Gd-DTPA in ENU-induced rat glioma model-dynamic study using animal MRI system- 97th Annual Meeting of American Society of Cancer Research, Washington DC, USA, April 1-5, 2006

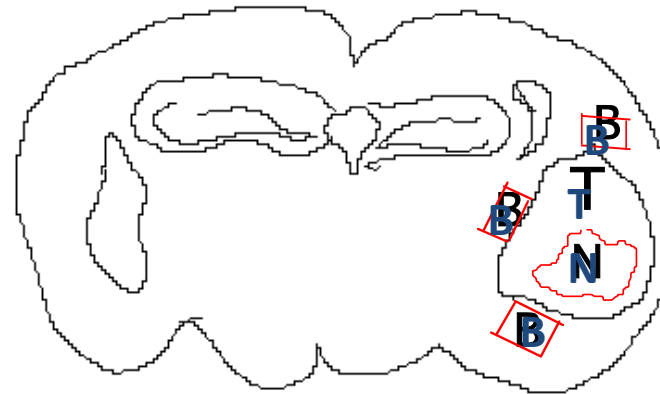
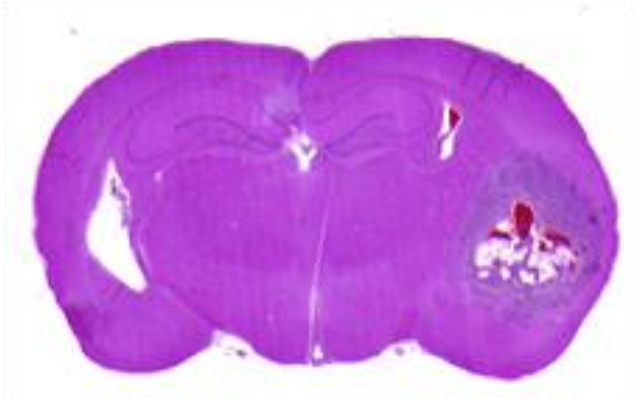
Measurements of Signal Intensity in Brain Tumor and Surrounding Brain

T: solid region

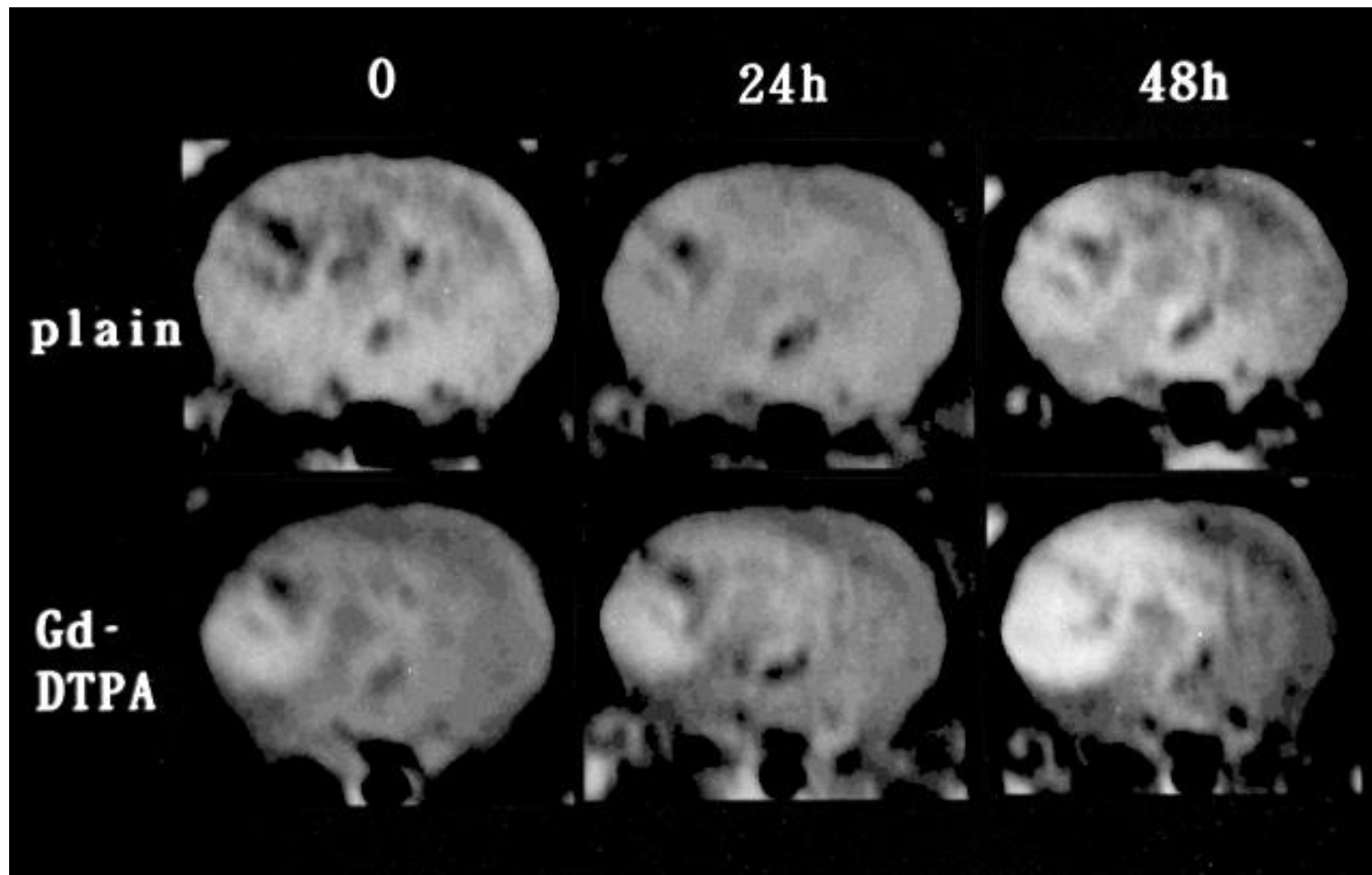
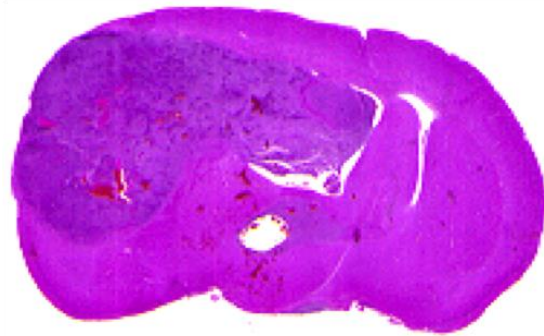
N: necrotic region

B: surrounding brain

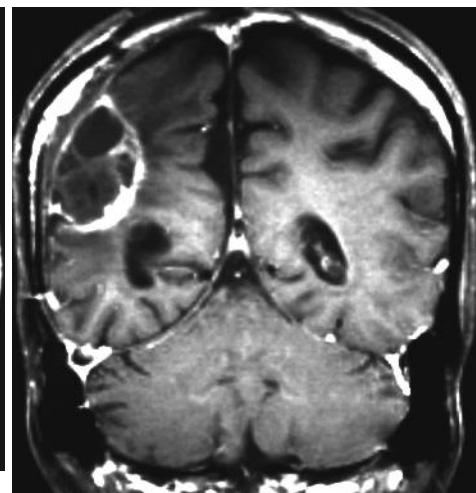
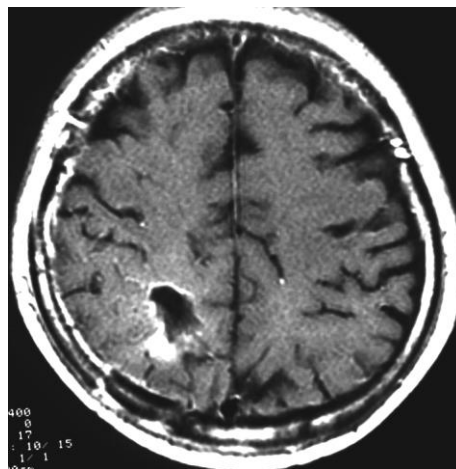
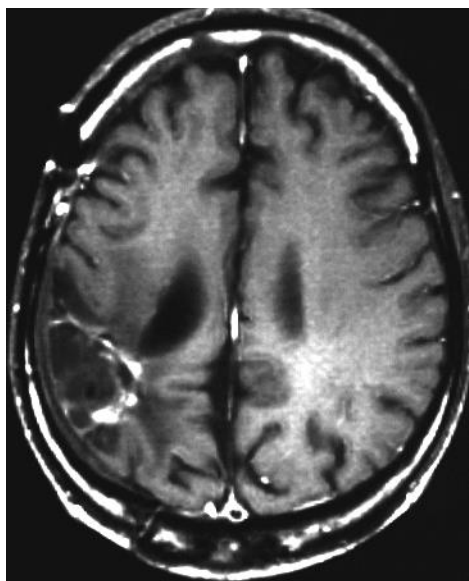
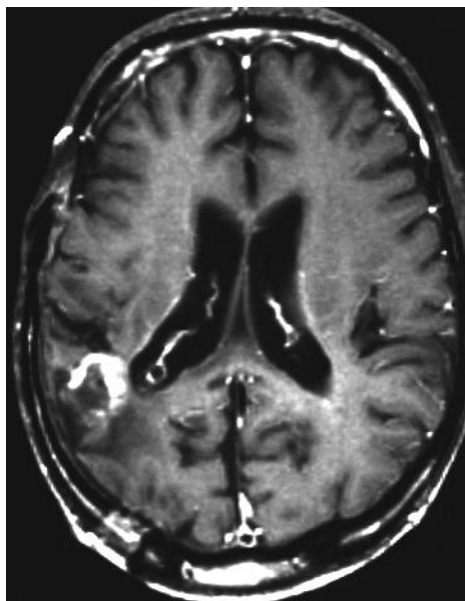
T: tumor



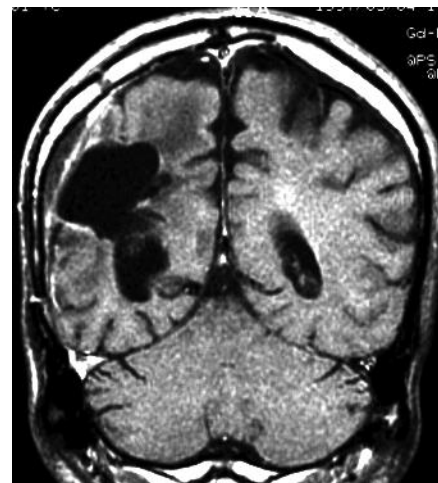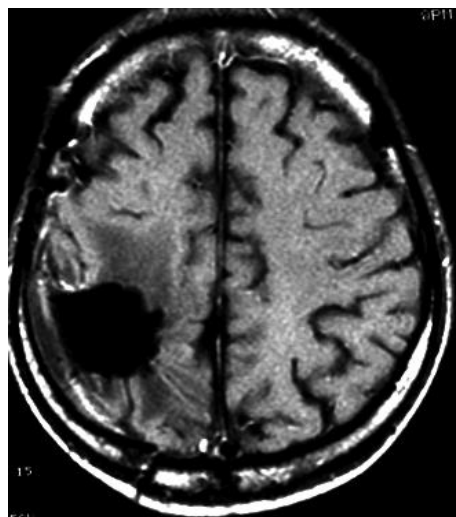
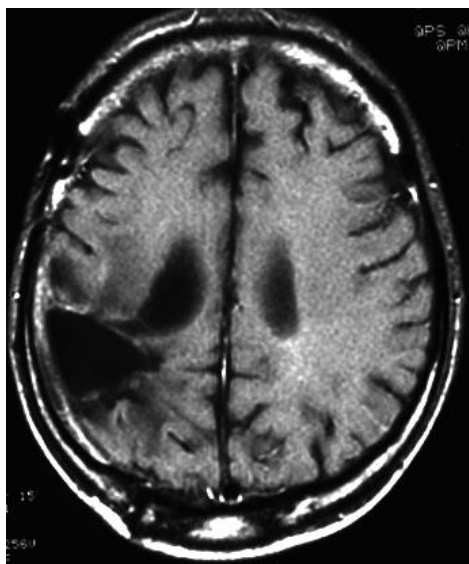
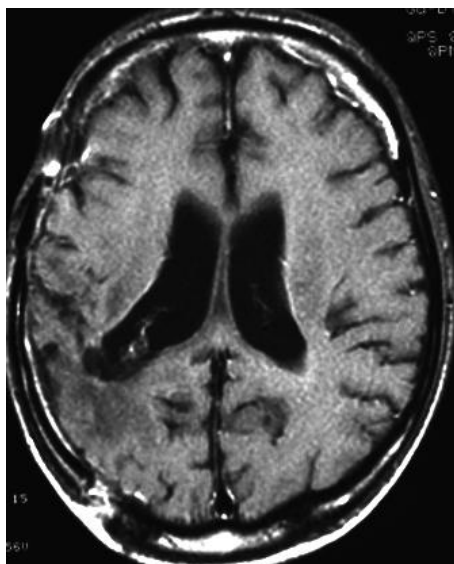
Signal intensity of tumor was measured in solid region of the tumor and signal intensity of surrounding brain was expressed as a mean value of the three regions.



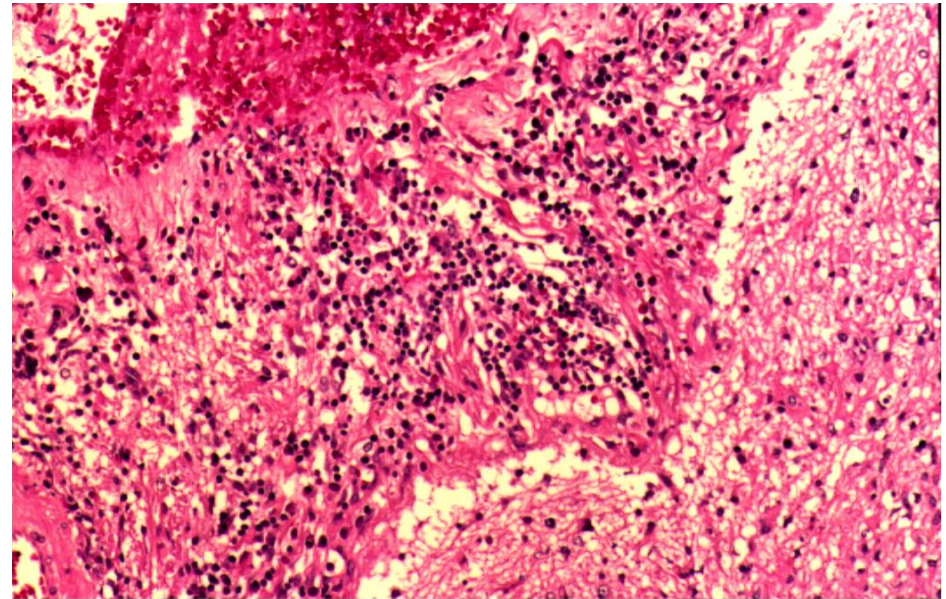
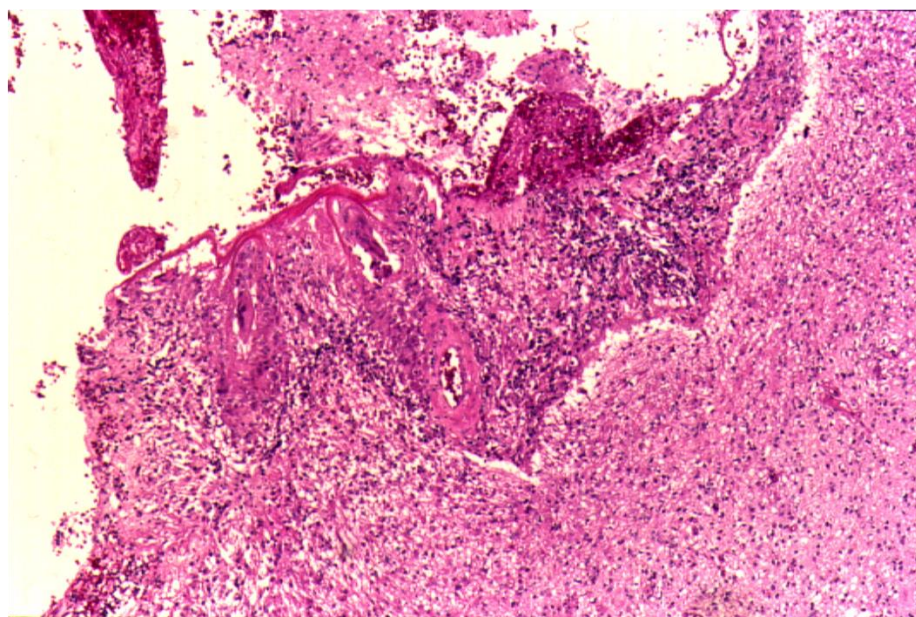
Pre-treatment



Post-treatment



Histological findings of surgical specimens from patient with preoperative IL-2 injection



Routine treatment

Latest Standard Therapy for Malignant Glioma: Surgery + Chemotherapy + Radiation

Chemotherapy (temozolomide)(1999)(Malcolm Stevens: Aston Univ. Birmingham)

A derivative of imidazotetrazine(dacarbazine)

Therapeutic benefit depends on the ability to alkylate / methylate DNA

Epigenetic silencing of MGMT, AGT or AGAT gene prevent the synthesis of the enzyme

DNA repair enzyme: O⁶-methylguanine-DNA methyltransferase(MGMT)

*MGMT陰性例で腫瘍縮小効果が著明であるのに比して陽性例は効果が見られない

(MGMT methylation did predict improved overall survival (23.2 versus 14.3 months, P<0.001) and PFS (14.1 versus 8.2 months, P<0.001).

How to overcome over-expression of MGMT

- *STAT3 Inhibition Overcomes Temozolomide Resistance in Glioblastoma by Downregulating MGMT Expression (北海道大学) 、 proteasome inhibitor MG132も関与？
- *Levetiracetam enhances p53-mediated MGMT inhibition and sensitizes glioblastoma cells (U138, LN18 and T98G) to temozolomide. Neuro-Oncol 12:917-927, 2010
- *Glycogen synthase kinase 3 β inhibition sensitizes human glioblastoma cells to temozolomide by affecting O⁶-methylguanine DNA methyltransferase promoter methylation via c-Myc signaling
- *A triple strategy including siRNA and the PARP inhibitor olaparib further improved the killing effect of temozolomide
- *anti-MGMT sh(short hairpin)RNA therapy
- *HDAC inhibitor
- *DNA-PK inhibitor NU7026: knock down Rad51 or BRCA2->MGMT減少

Sodium butyrate induced cellular senescence and inhibited invasion of cancer cells with distinct mechanism

2624

Kazuyuki Itoh¹⁾, Hidemitsu Nakagawa²⁾ and Kiyoko Yoshioka¹⁾

(¹⁾Osaka Medical Center for Cancer, and (²⁾Nozaki Tokushukai Hosp., Osaka, Japan)

Intracellular HDACs Inhibitor?

Bolden JE et al. Nat Rev Drug Discov ; 9, 2006

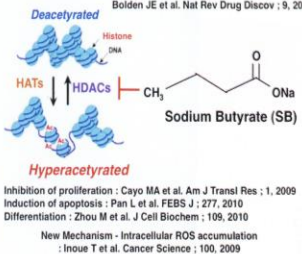


Fig. 1 Effect of SB on the growth in A172 human glioblastoma cells

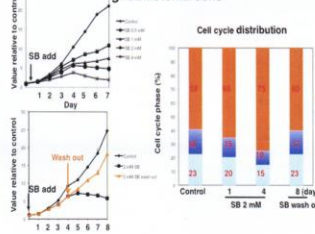


Fig. 2 Effect of SB & HDACi (TSA) on senescence associated β -galactosidase (SA- β -gal)

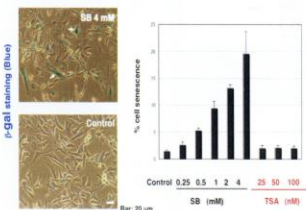


Fig. 3 RT-PCR and IB of p21 Waf1/Cip1, p27/Kip1 & p53 in 2 mM SB treated A172 cells

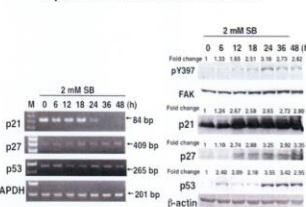

Fig. 4 Effect of SB on the motility, invasiveness & morphology in A172 cells

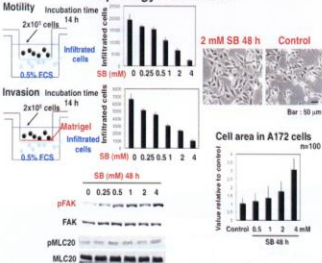


Fig. 5 Effect of SB on FAK phosphorylation

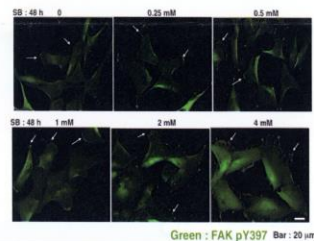


Fig. 6 Effect of SB on p21 Waf1/Cip1, p27/Kip1, p53, SIRT1, FAK phosphorylation & MLC phosphorylation

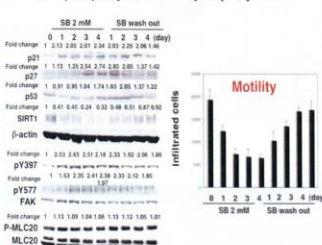


Fig. 7 Downregulation of CDKN1A(p21, Cip1) protein level by CDKN1A(p21, Cip1) siRNAs (72 h) on motility of A172 cells

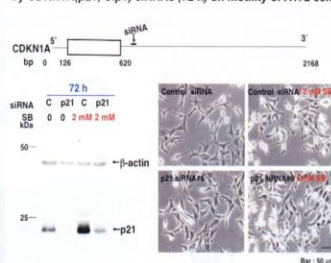
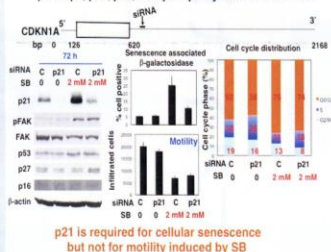


Fig. 8 Effect of SB & CDKN1A(p21, Cip1) siRNA on p21 Waf1/Cip1, p27/Kip1, p53, p16, FAK phosphorylation in A172 cells



Summary of experimental results

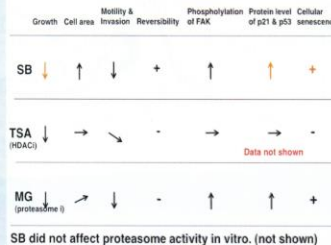
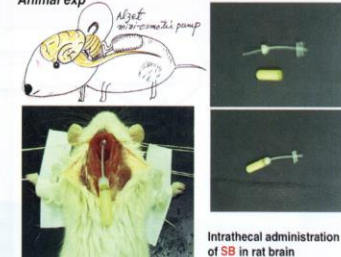
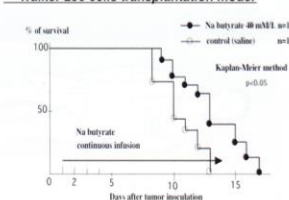


Fig. 9 Alzet mini osmotic pump



Walker 256 cells transplantation model



Conclusion

SB reversibly inhibited cell growth, induced cellular senescence via p21 protein stabilization. SB also reversibly inhibited cellular motility, invasion with distinct mechanism.

This physiological metabolite would be a good candidate for anti-invasive therapy without severe adverse effects.

Mechanism corresponding to the inhibition of motility induced by SB is currently under investigation, employing metabolome analysis.

Sodium Butyrate (酪酸ナトリウム) について

1.Sodium butyrate (NaB : 酪酸ナトリウム)は自然に存在する単鎖飽和脂肪酸であり培養系で種々の腫瘍細胞の成長抑制、遺伝子変換や分化の促進に使用されてきた。食物の代謝物質として人腸管膜の細胞や門脈血中に高濃度に存在するが故に、この薬剤の悪性腫瘍細胞の分化の促進からアポトーシス,および少ない代謝への影響と腫瘍細胞の浸潤抑制効果を期待した臨床応用が期待されてきた。しかしながら血中におけるその半減期は6分と短く、その効果は可逆性であるが故に標的腫瘍で効果を発揮するには有効濃度での持続投与が必要になる。一方髄液腔での半減期は血清におけるよりも長いことが推測される。

2.細胞周期抑制蛋白であるp21 と p27がsodium butyrateによって増加する。

3.Sodium butyrate はmM濃度で形態学的にもそしてbiochemicalな変化を可逆性にもたらず。主な直接的な効果はhistone deacetylase 酵素を抑制し、その結果histonecore 蛋白のhyperacetylation をもたらずとされている。そしてhistone deacetylase 抑制の機序はprotein phosphatase の導入がありうると考えられている。

3.ヒトretinoblastomaの培養系での vincristine, cisplatin あるいはcamptothecin のsodium butyrate による抗腫瘍効果増強が報告され、種々の機序の可能性が推測されている。

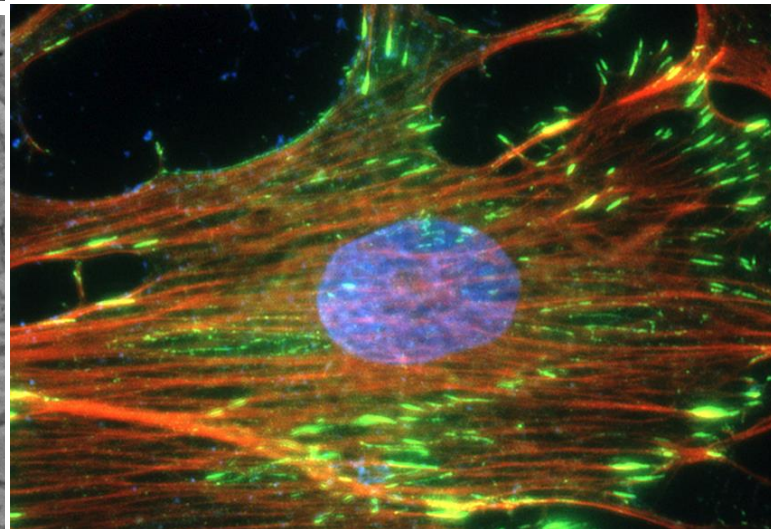
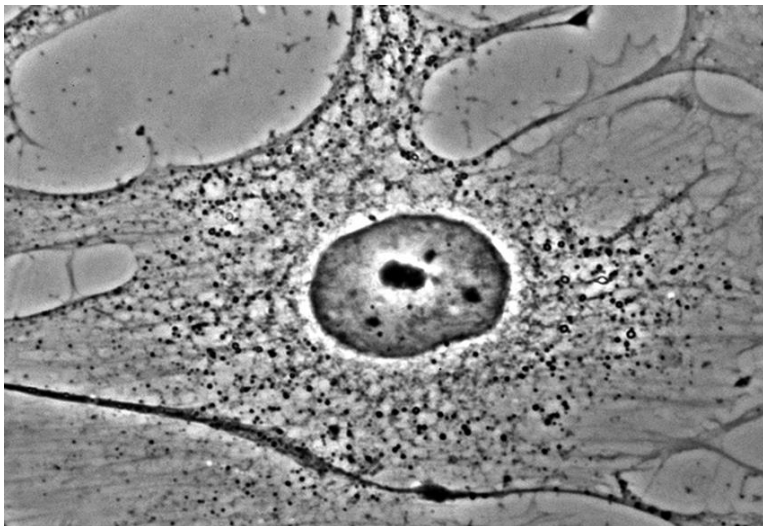
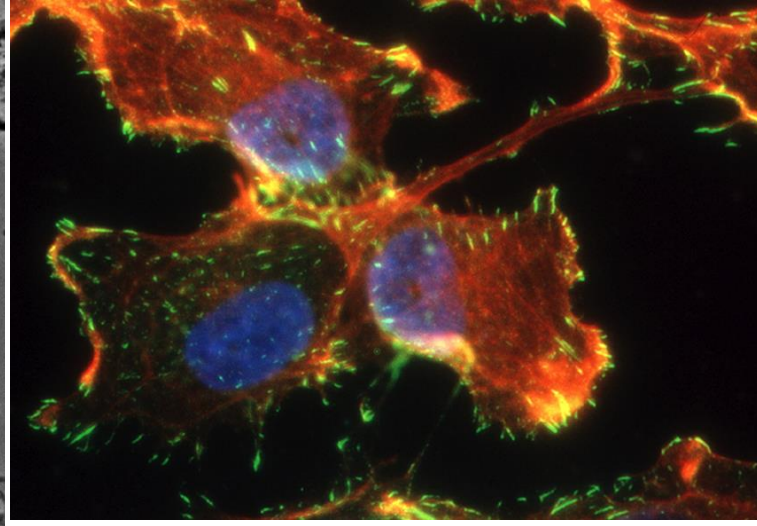
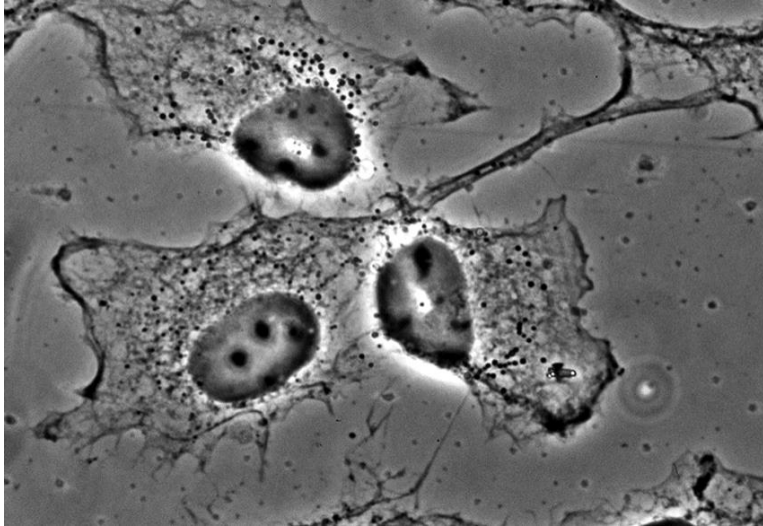
4.Sodium butyrate は放射線との相乗効果を示す。

Sodium Butyrate(NaB)の持続的腫瘍腔内投与療法

NaBは**in vitro**で濃度依存性に殺細胞効果を示し、ラット癌性髄膜炎モデルで同様の効果を示し、**in vitro**では初代神経培養および星細胞培養にて極めて少ない毒性を示し、また**Walker 256**細胞やヒト**A-172**神経膠芽腫細胞での浸潤抑制効果を報告した。これらの結果より、**NaB**の髄腔内あるいは腫瘍腔内の持続投与は悪性神経膠腫ならびに癌性髄膜炎のよい治療法になることが示された。これらの結果をもって当院倫理委員会に臨床応用を申請し、その許諾をもって試験を開始した。

1. Nakagawa H, : Intrathecal or intracavitary administration of sodium butyrate to treat neoplastic meningitis and malignant glioma. 95th Annual Meeting of AACR, Orlando, USA, March, 2004
2. Nakagawa H: Clinical trial of continuous intrathecal or intracavitary infusion of sodium butyrate for leptomeningeal carcinomatosis or recurrent malignant glioma. 96th Annual Meeting of American Society of Cancer Research, Anaheim, CA, USA, April 16-20, 2005
3. Nakagawa H,: Intrathecal or intracavitary administration of sodium butyrate in patients with malignant glioma-Basic research and Clinical trial. 17th International Congress on Anti-Cancer Treatment (ICACT), Paris, France, January 30~Feb.2, 2006.
4. H Nakagawa, : Clinical results of continuous intrathecal or intracavitary administration of sodium butyrate for patients with recurrent and progressive malignant glioma. Experience with 23 cases 43rd Annual Meeting of American Society of Clinical Oncology (ASCO), June 1-5, 2007, McCormick Place, Chicago, IL, USA
5. Nakagawa H: Evaluation of immunoreactivity of monocarboxylate transporter (MCT) 1 in recurrent and progressive malignant glioma(MG): Speculation of the favorable factor in immunoreactivity in the response to the continuous intrathecal infusion of sodium butyrate (NaB). April 12-16, 2008, San Diego, Ca
6. Nakagawa H: Correlation between immunoreactivity of monocarboxylate transporter 1 in malignant glioma and tumor response to continuous intrathecal infusion of sodium butyrate, ECCO15-ESMO34, September 20-24, Berlin, Germany, 2009
Association for Cell Biology. Philadelphia, PA, December 11~15, 2010
7. Nakagawa H : Intrathecal Sodium Butyrate for Neoplastic Meningitis- Experimental Study and Clinical Trial Stockholm, Sweden, September 23~27, 2011.
8. Kazuyuki Itoh and Hidemitsu Nakagawa: Sodium butyrate induced cellular senescence and inhibited invasion of cancer cells with distinct mechanism. AACR 2013, 6-10, Washington DC, USA

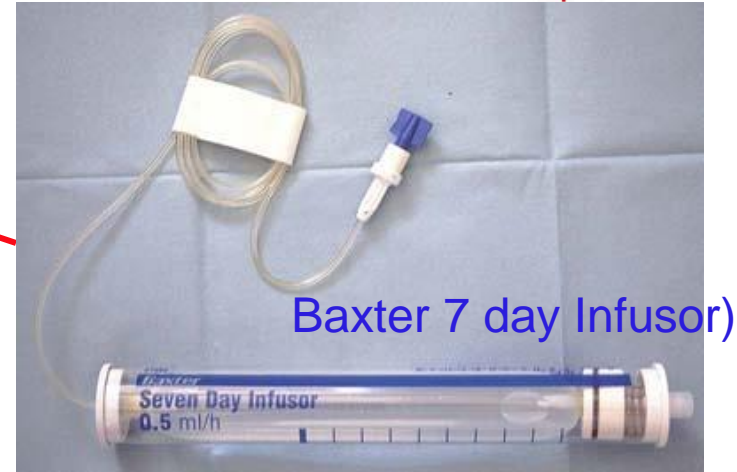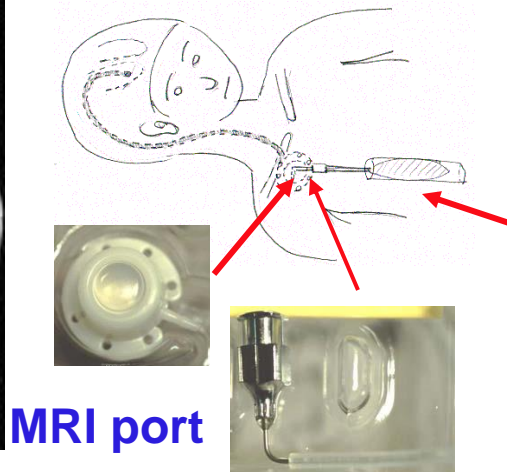
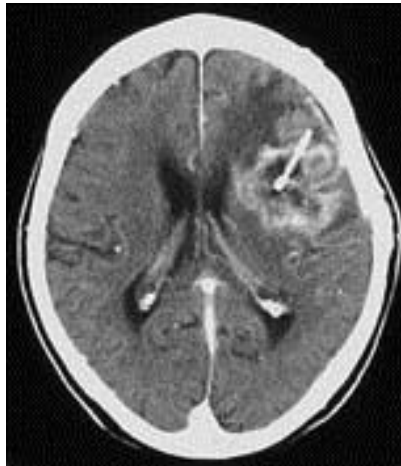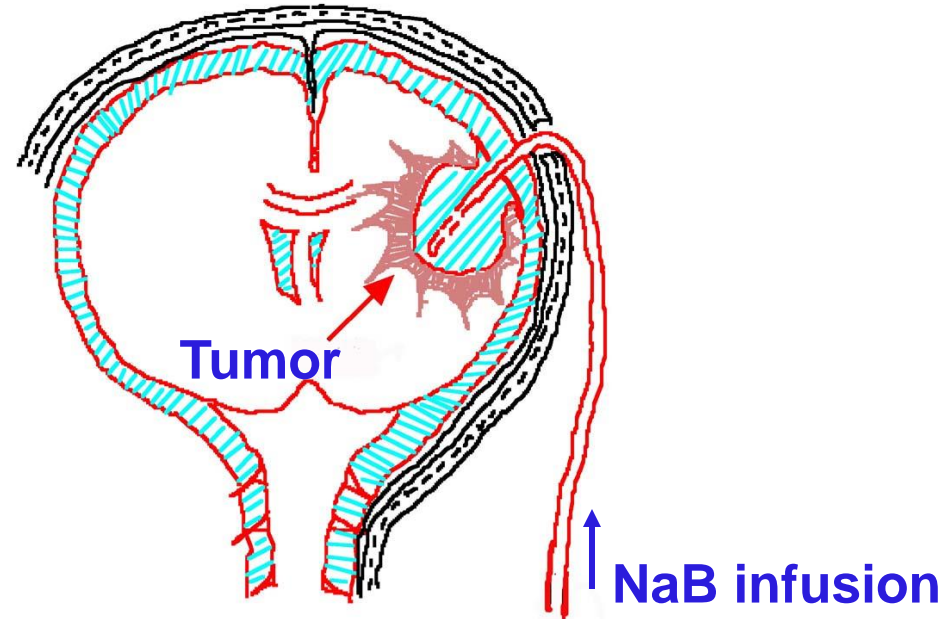
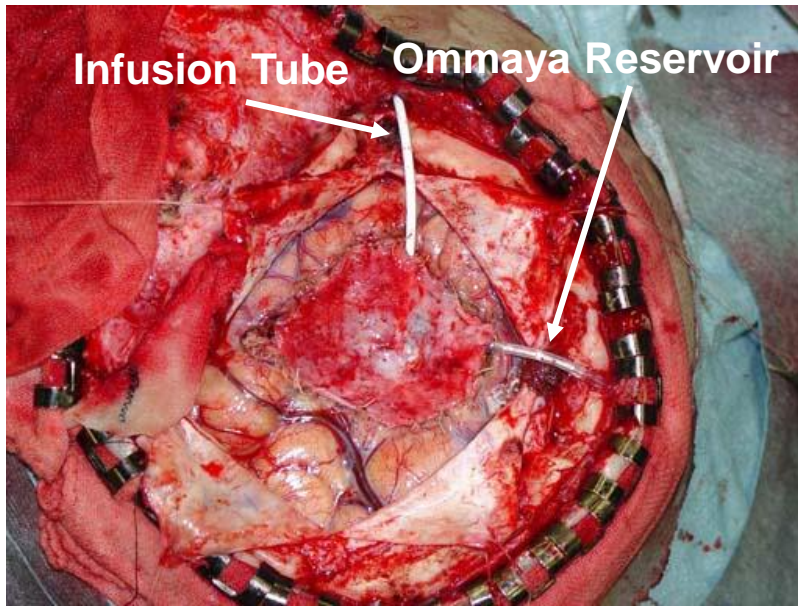
Morphological changes induced by sodium butyrate (SB) in Walker 256 cells



Red: F-actin **Green: vinculin**

Bar : 20 μm

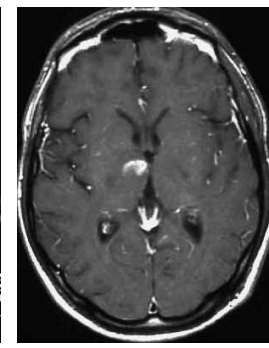
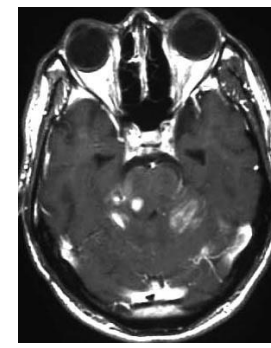
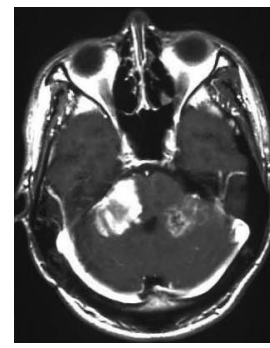
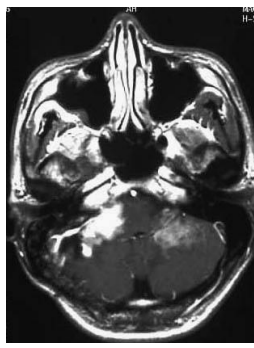
Clinical procedure for continuous intracavitary administrations of sodium butyrate for recurrent or progressive malignant glioma



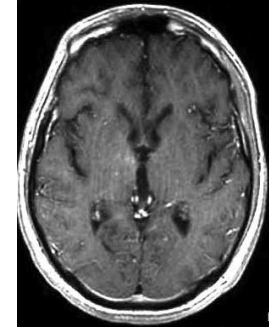
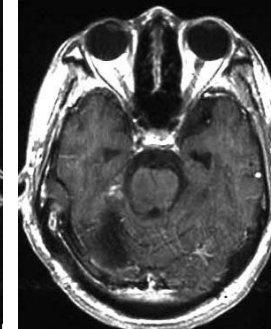
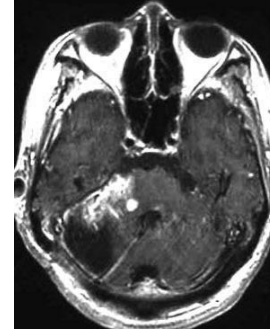
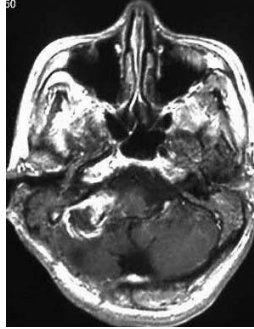
Case 6 : anaplastic astrocytoma

Before

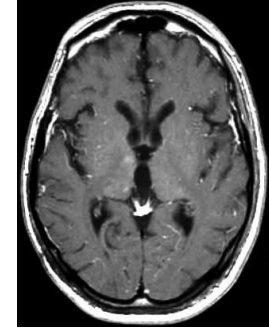
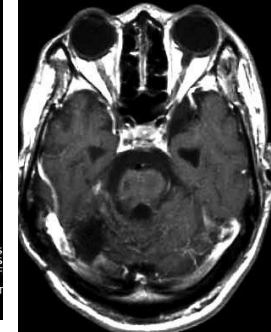
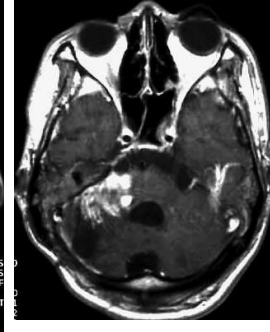
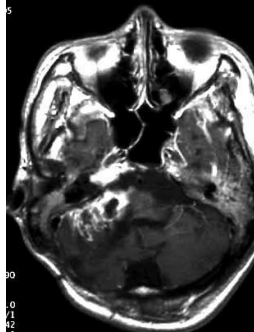
**Controlled respiration by
respirator**



3.0 mos.

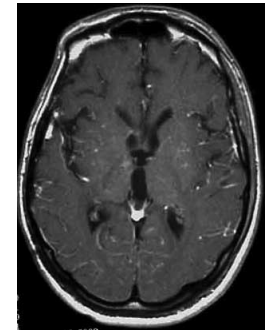
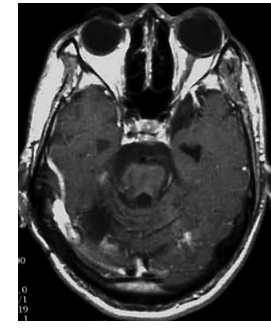
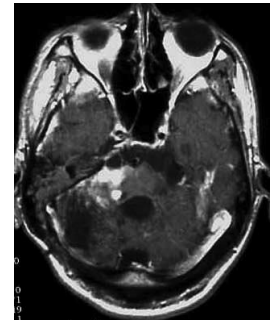
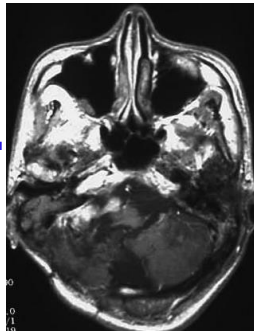


Possible oral intake 9.0 mos.



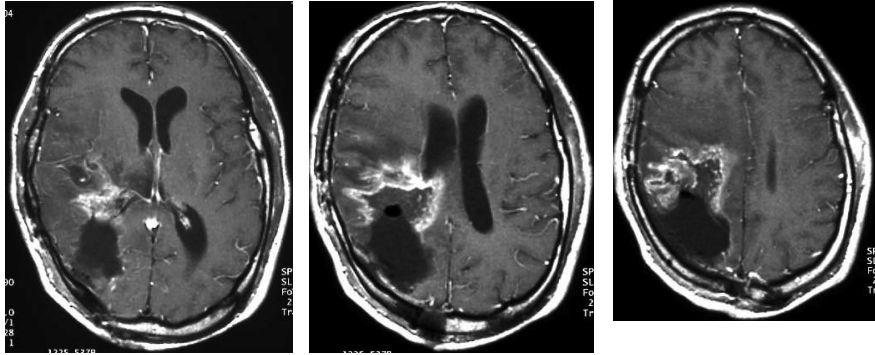
13.0 mos.

response, PFS: >13.0 mos

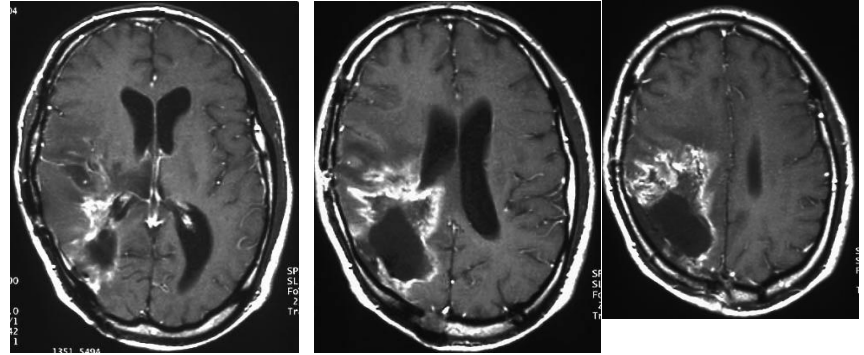


Case 9: anaplastic astrocytoma

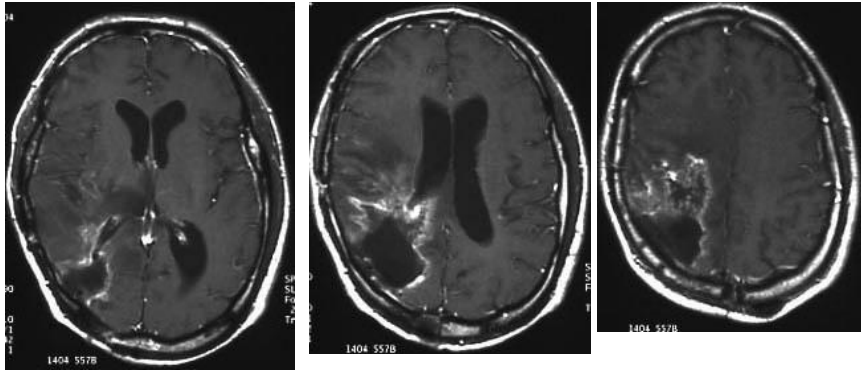
before



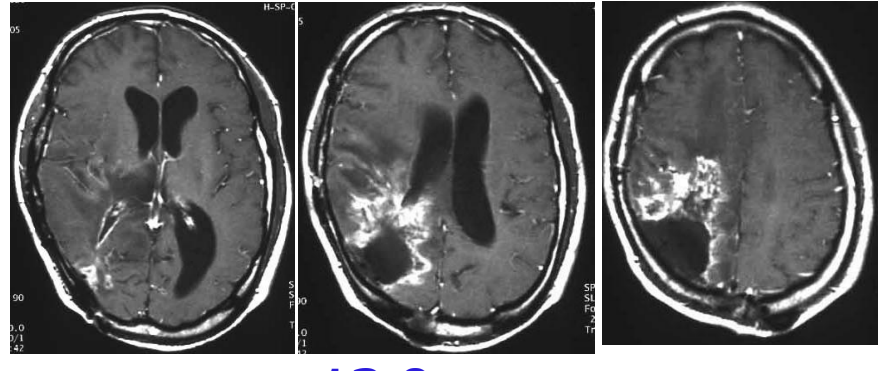
2.5 mos.



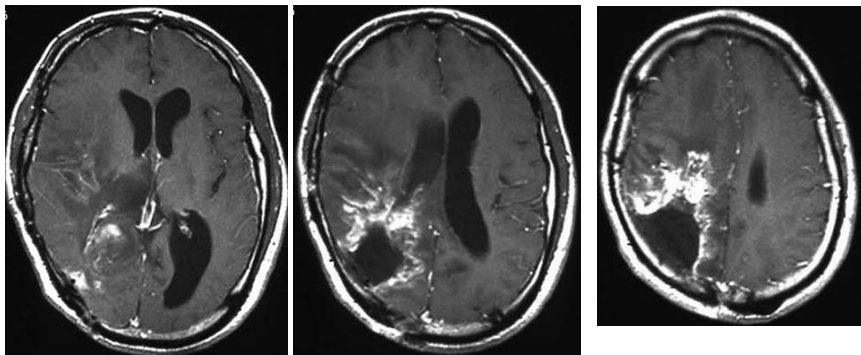
5.0 mos.



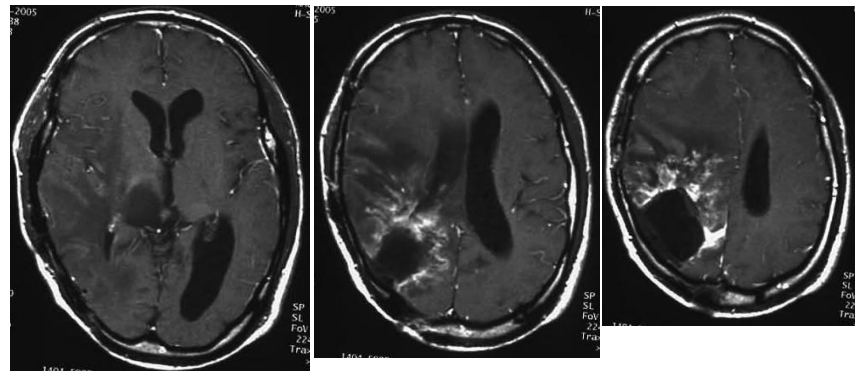
8.0 mos.



10.0 mos.

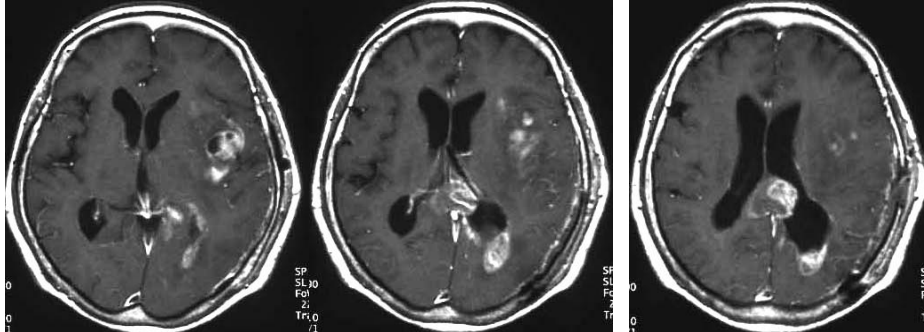


13.0 mos.

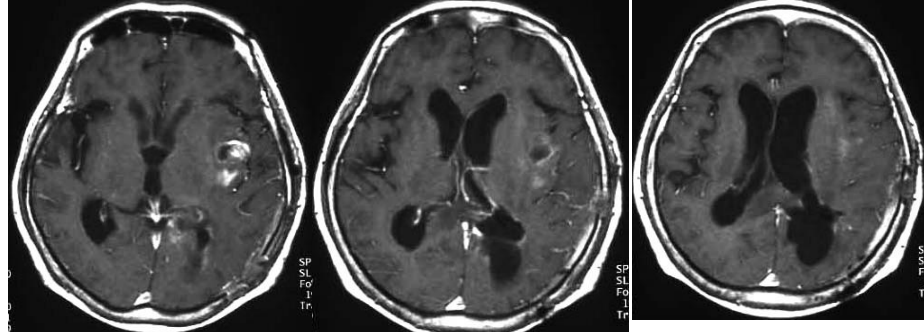


Case 14: glioblastoma

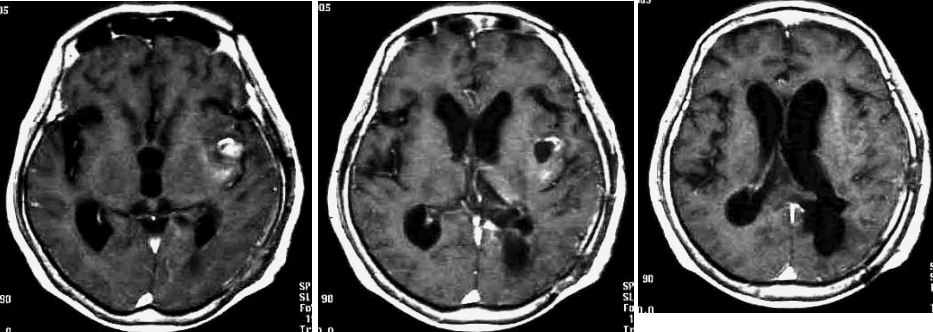
Before



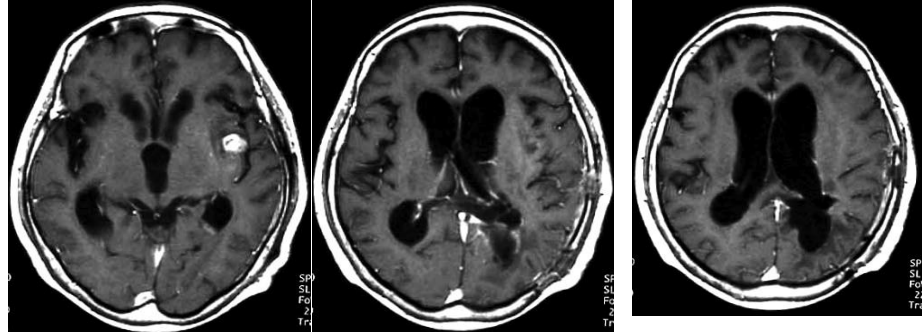
2.0 mos.



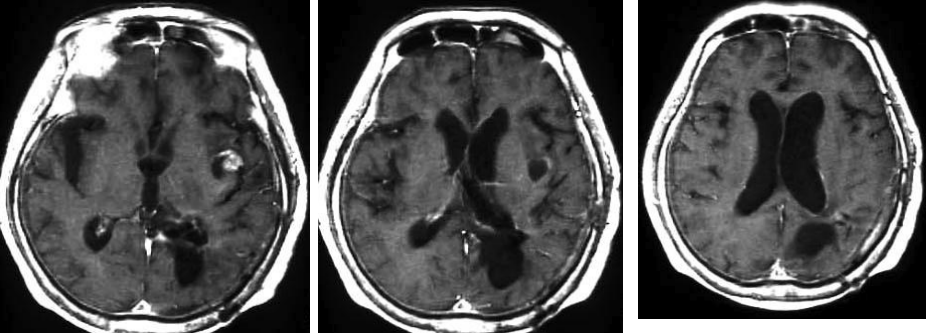
3.0 mos.



4.0 mos.



5.0 mos.



6.0 mos.

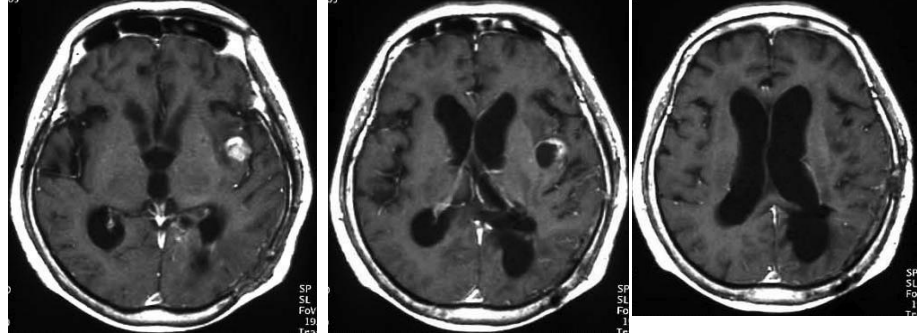
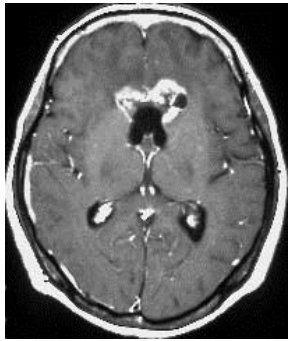


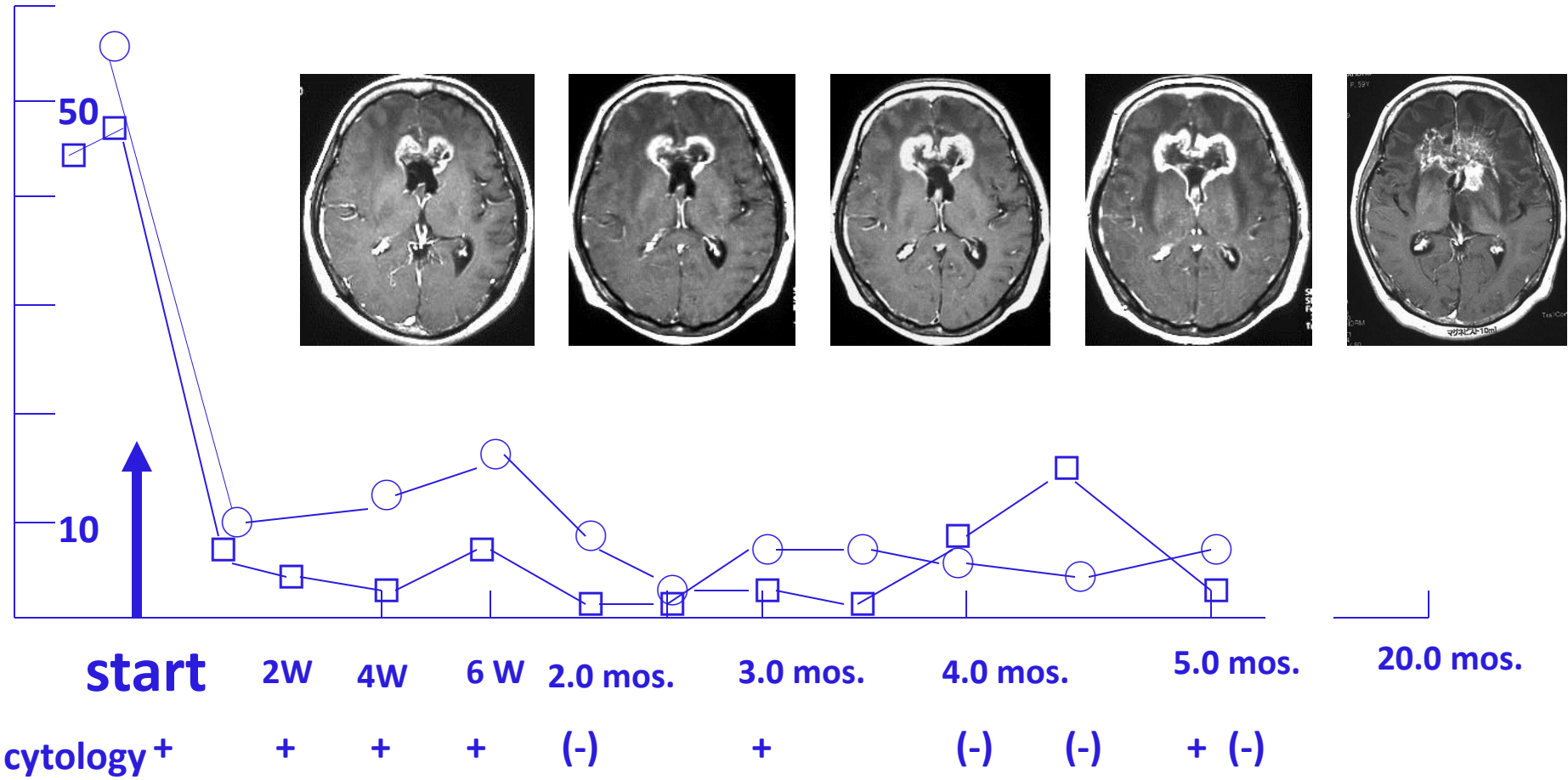
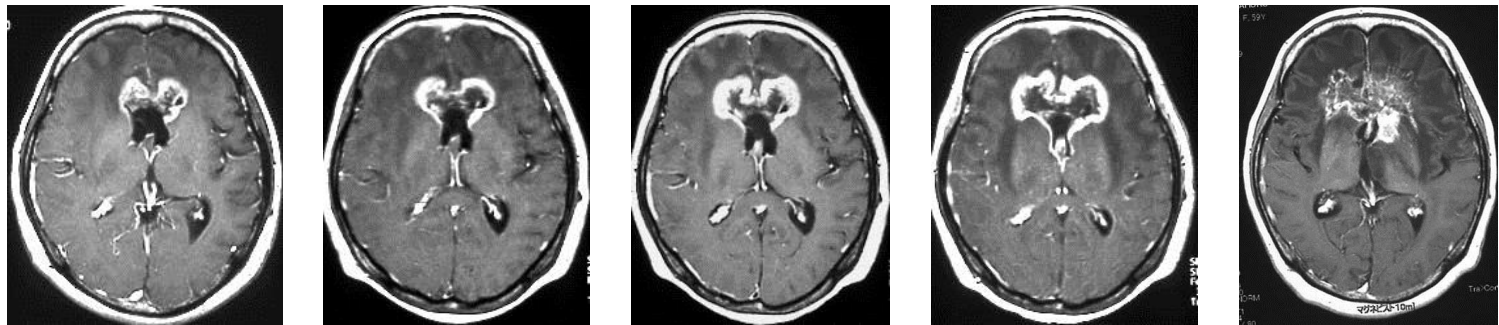
Fig.8

Case 3: AA with CSF dissemination of tumor cells

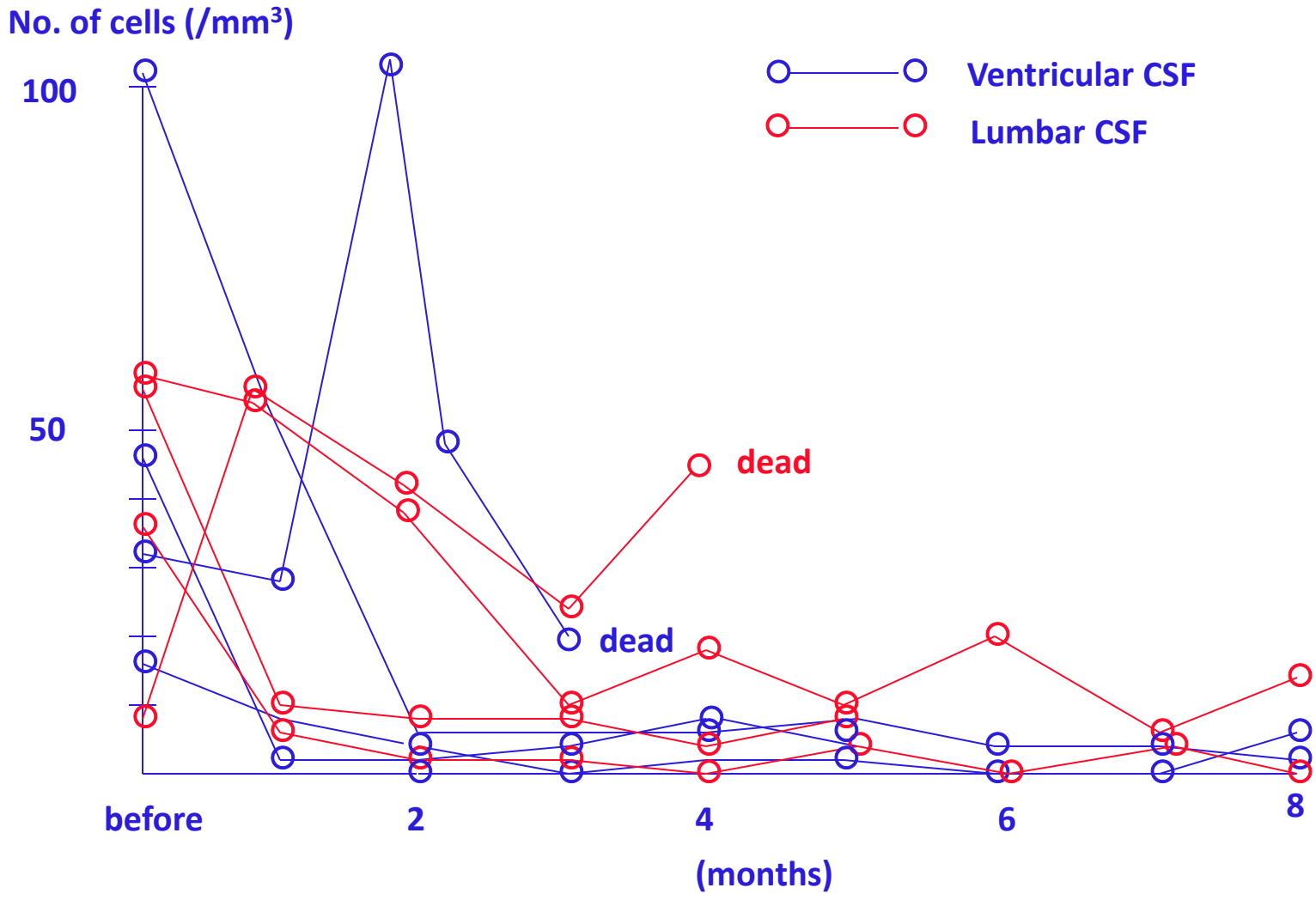


○—○ lumbar CSF
□—□ ventricular CSF

No. of cells



Response to continuous intrathecal NaB infusion in 5 patients with cerebrospinal fluid dissemination of tumor cells.



結論

40年程前に新しいニトロソウレア系抗癌剤としてBCNU,CCNU,MeCCNUの出現が見られ、本邦でもACNUの出現にて若年齢の症例で神経膠芽腫の長期生存例が見られるようになった。われわれも38、35、34、25年の長期生存例を経験しているが、いずれもACNUと放射線療法を行った例で、20歳前後の若い年齢である以外特別な長期生存のfactorは発見できない。長期生存例の出現にかかわらず、平均生存期間については40年前の1年から1年6ヶ月程に延長したにすぎない。今後、手術摘出度の向上、新しい角度からの治療法や遺伝子解析からの分子標的治療の出現の芽がでてきており、今後40年後には平均生存期間は数年になっていることを期待する。